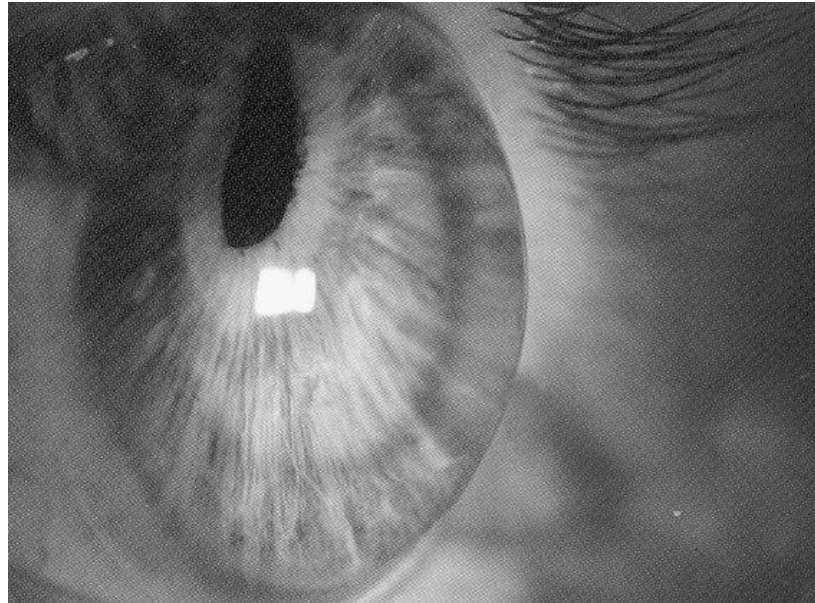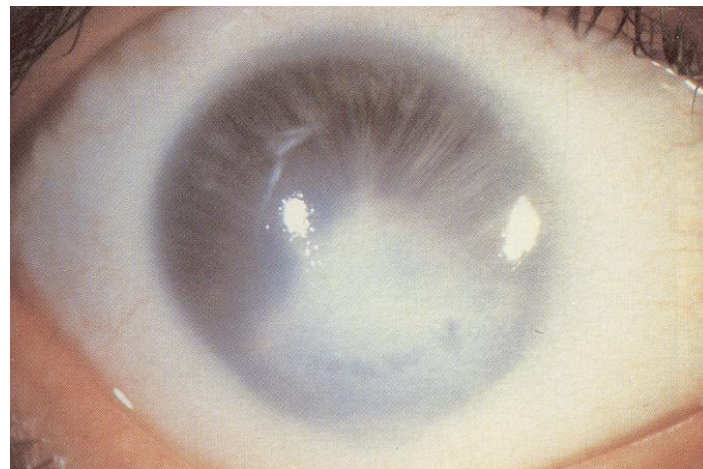
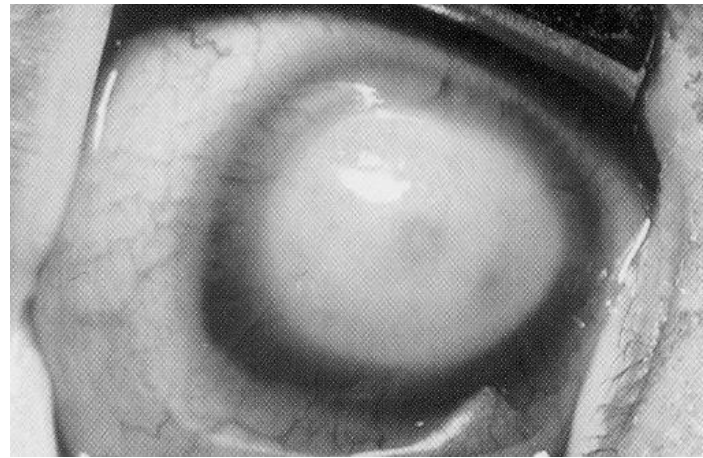
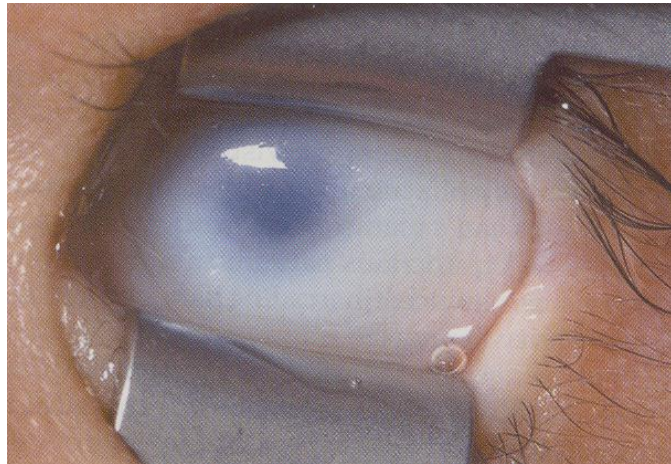
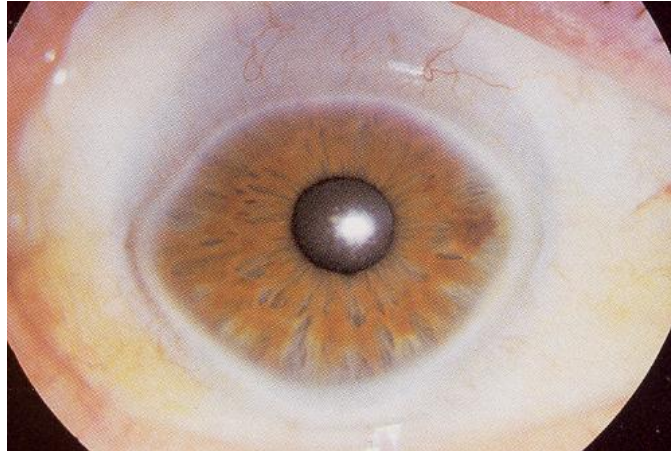


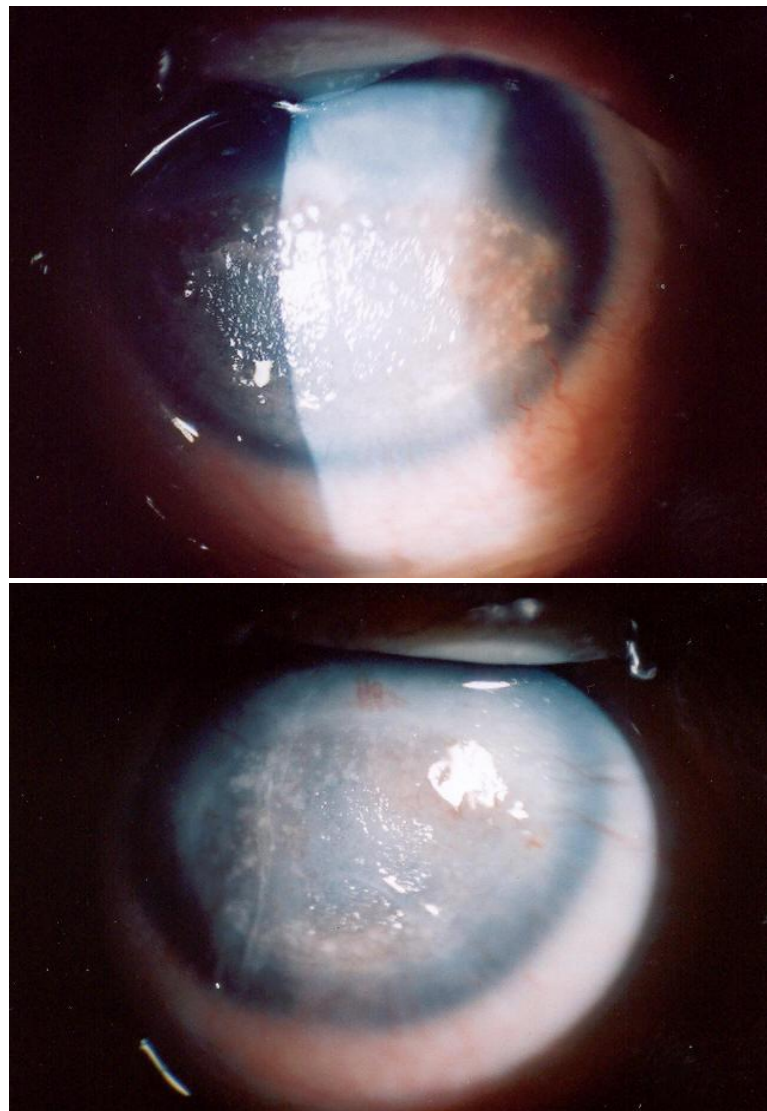
Obr. 16.3.1. Keratoglobus



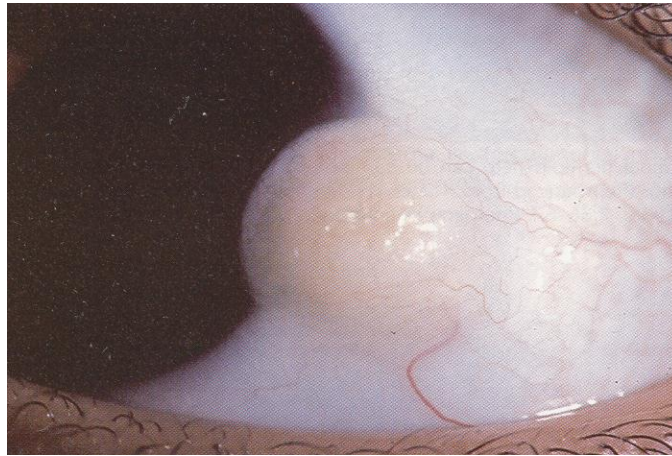
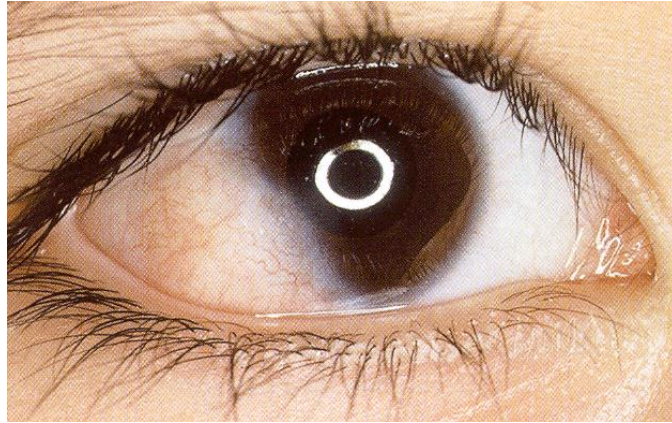
Obr. 16.3.2. Petersova anomálie



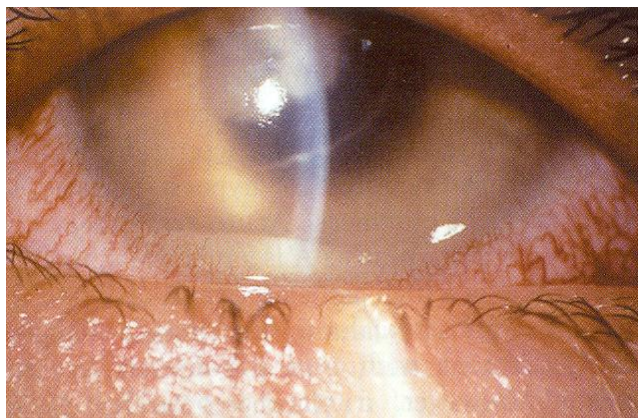Obr. 16.3.3. Sklerokornea



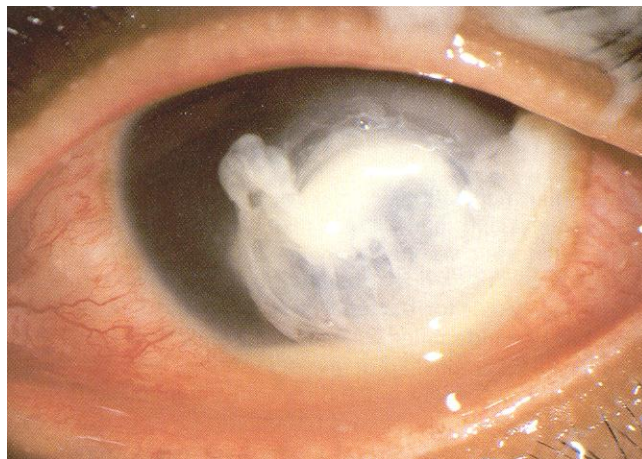
Obr. 16.3.4. Oboustranná expoziční a neuroparalytická keratopatie s rozsáhlou nesmáčivou lézí u 2-měsíčního kojence



Obr. 16.3.5. Dermoid rohovky

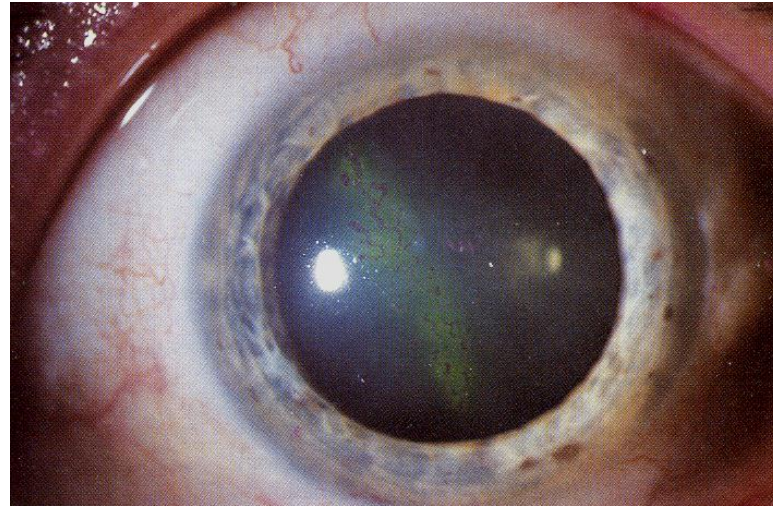


A

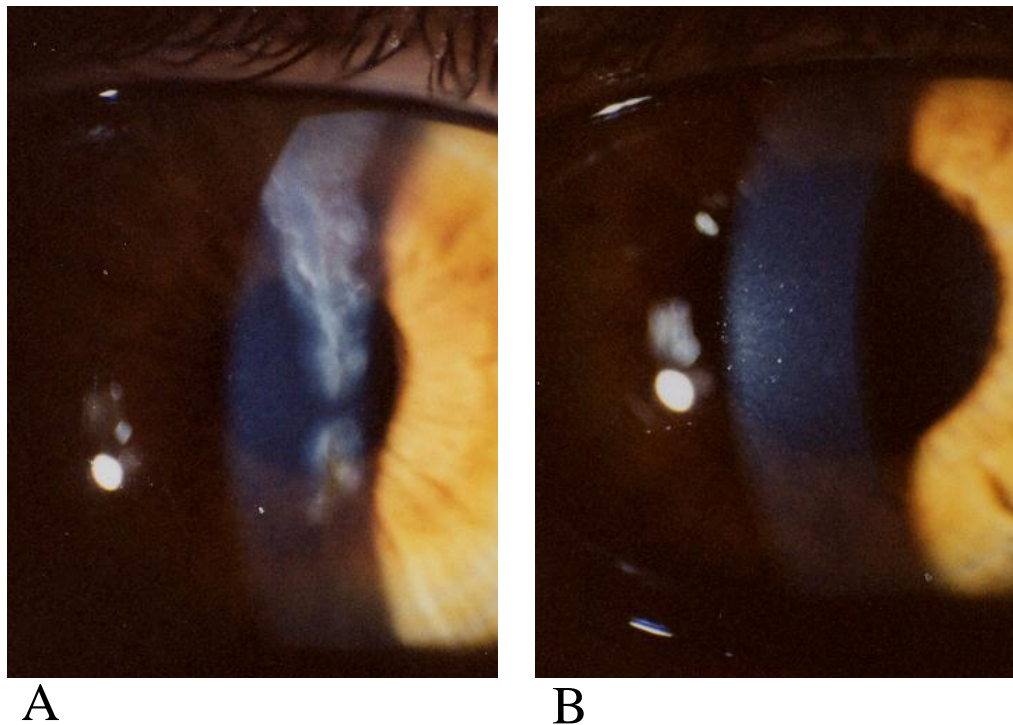


B

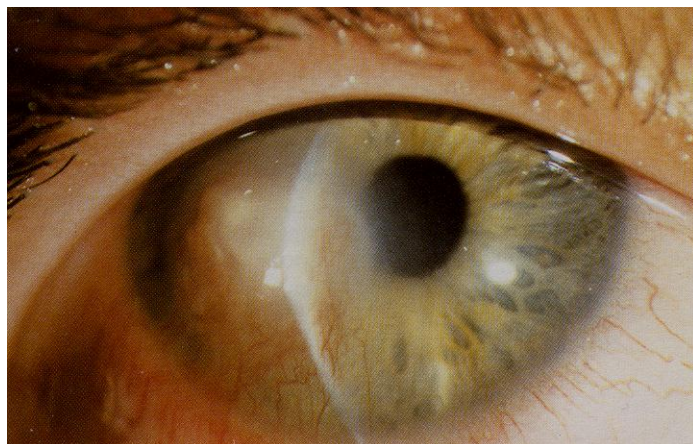
Obr. 16.3.6. Bakteriální keratitida
(A-*Streptococcus pneumoniae*,
B- *Pseudomonas aeruginosa*)



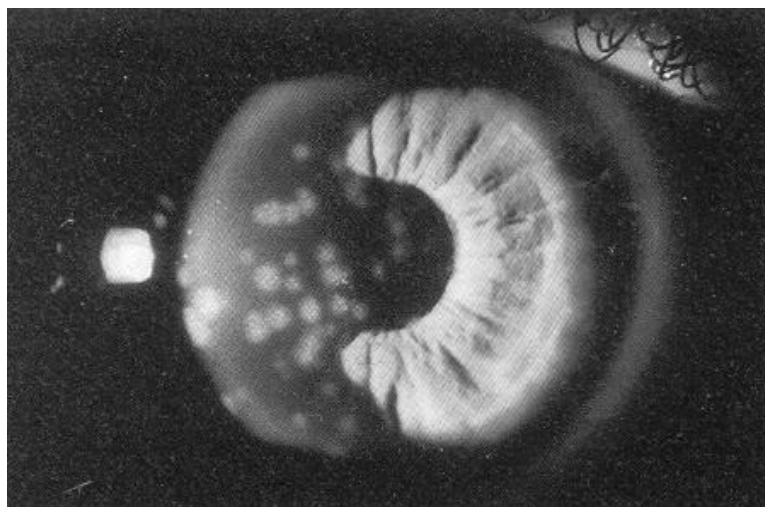
Obr. 16.3.7. HSV- dendritická keratitida



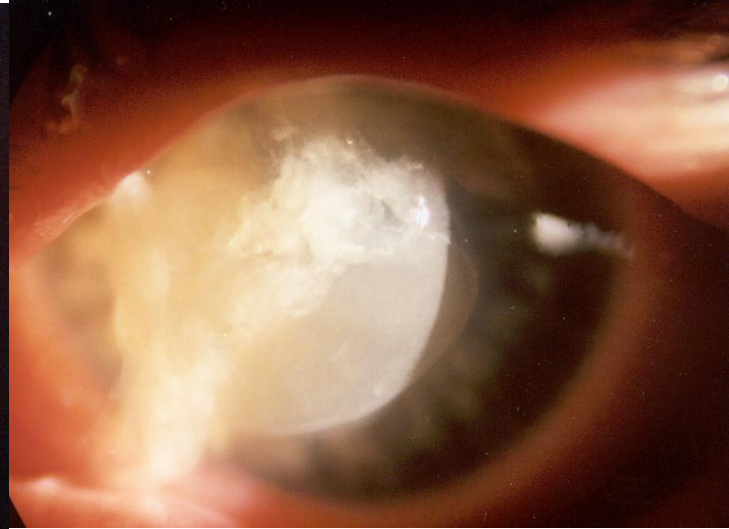
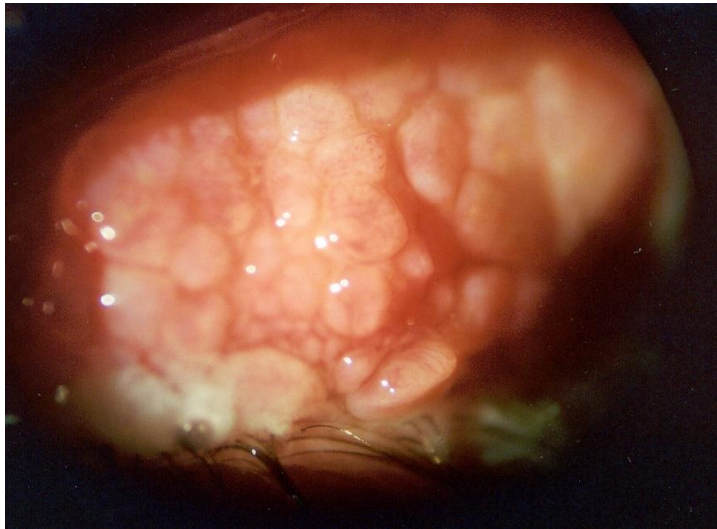Obr. 16.3.8. Postherpetická jizva rohovky u dítěte před (A, visus 6/24) a 3 roky po (B, vizus 6/9) fototerapeutické keratektomii (chlapec- věk 13 roků)



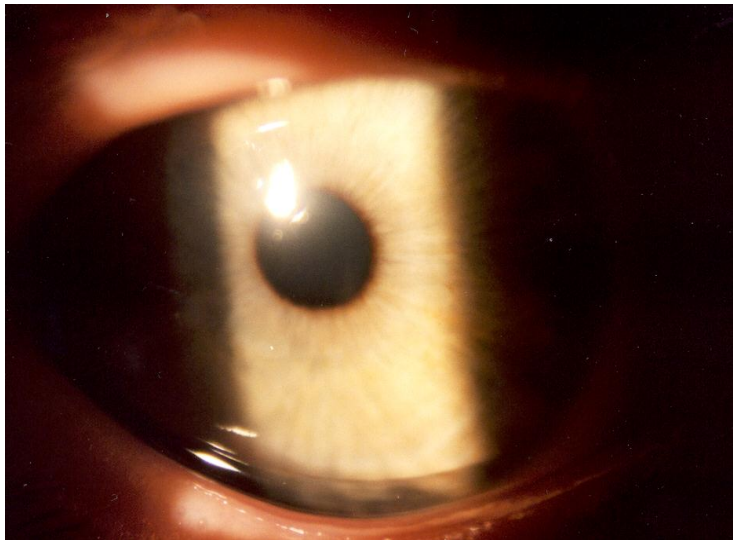
Obr. 16.3.9. Metaherpetický vřed rohovky



Obr. 16.3.10. Adenovirová keratitida

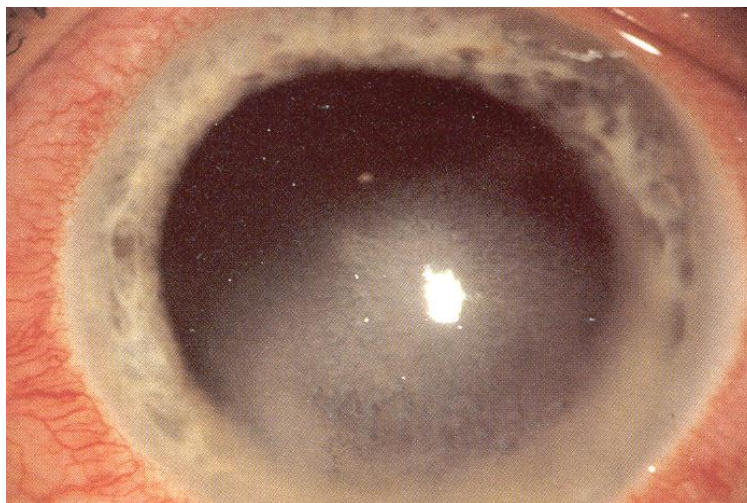


A

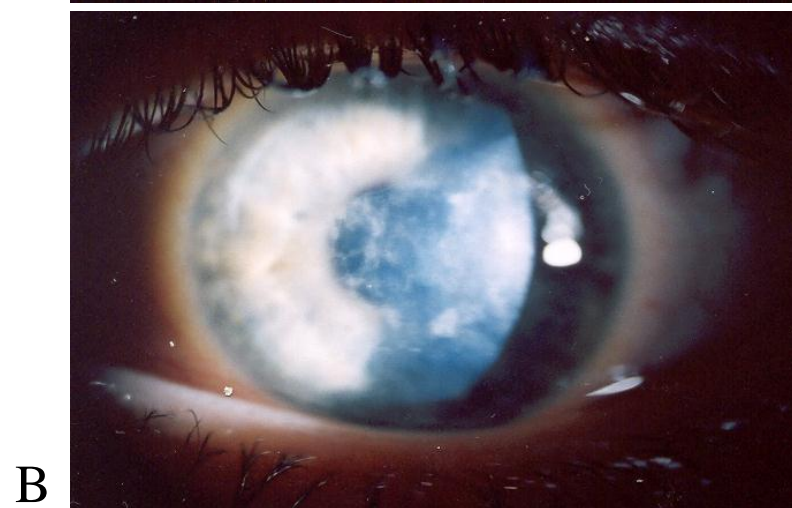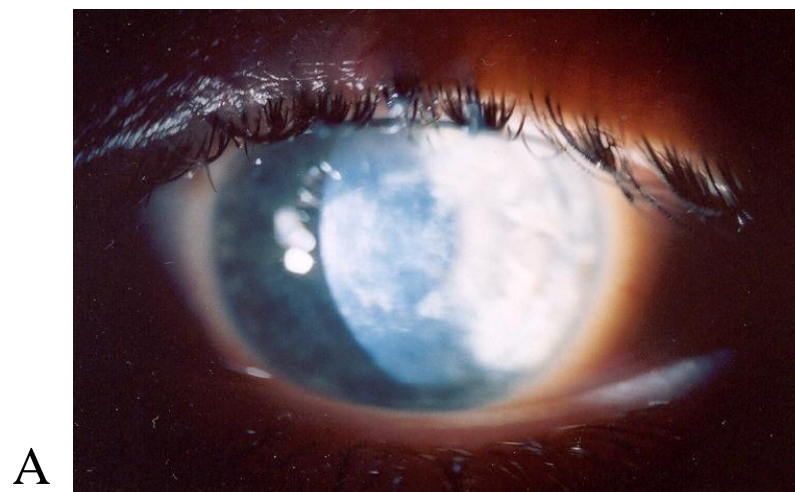


B

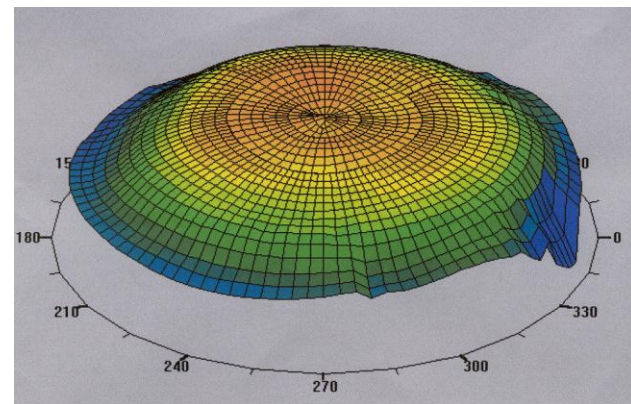
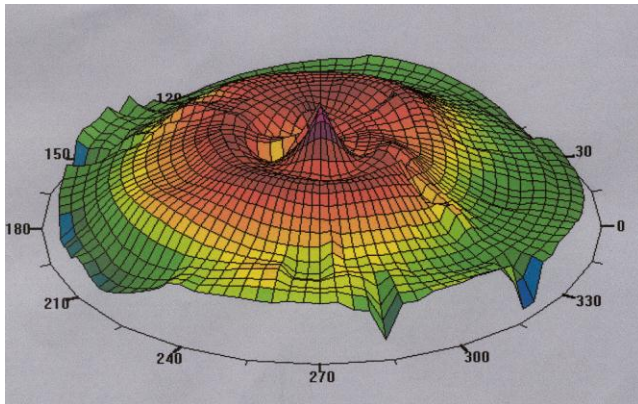
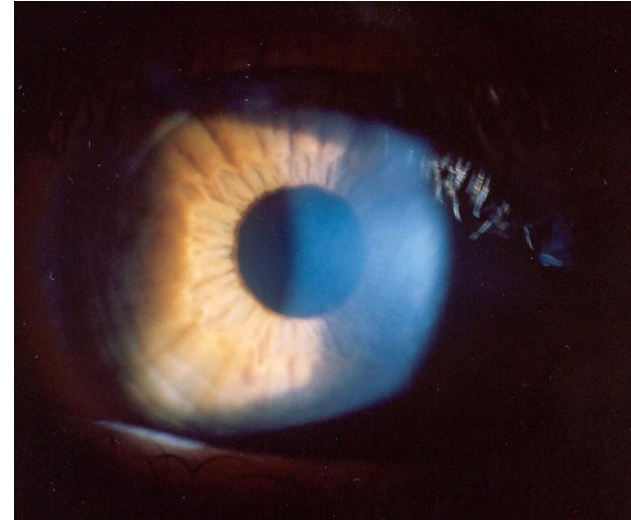
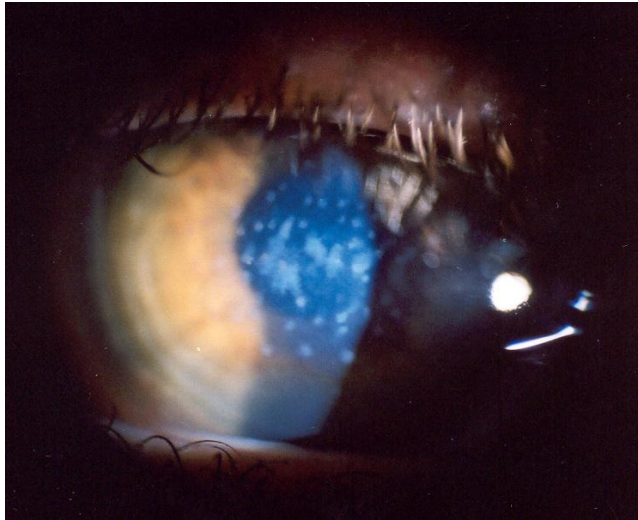
Obr. 16.3.11. Rohovková komplikace vernalní kerato-konjunktivitidy u 11-letého chlapce před (A) a 3 roky po PTK (B-Vizus 1m prsty zlepšen na 6/6)



Obr. 16.3.12. Intersiticiální keratitida (HSV etiologie)



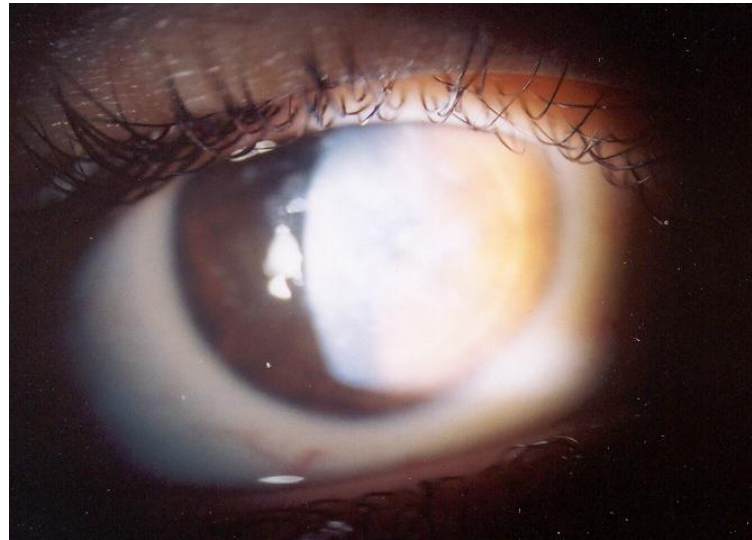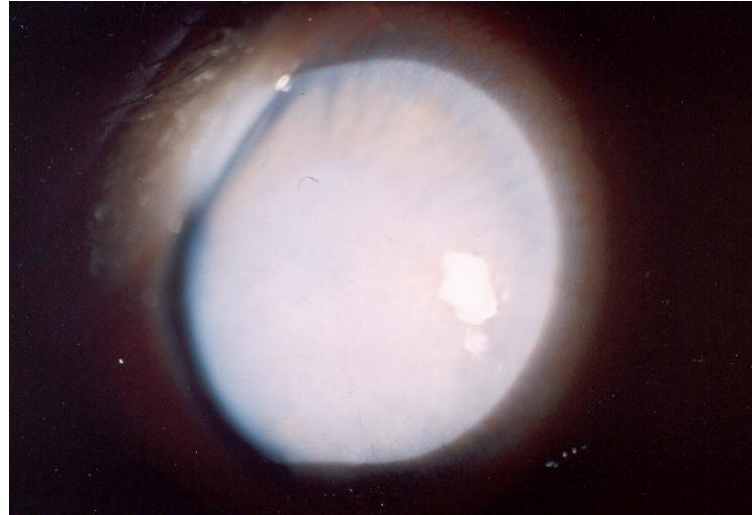Obr. 16.3.13. Reis-Bucklersova dystrofie
u 14-letého chlapce (A-pravé oko, B- levé oko)



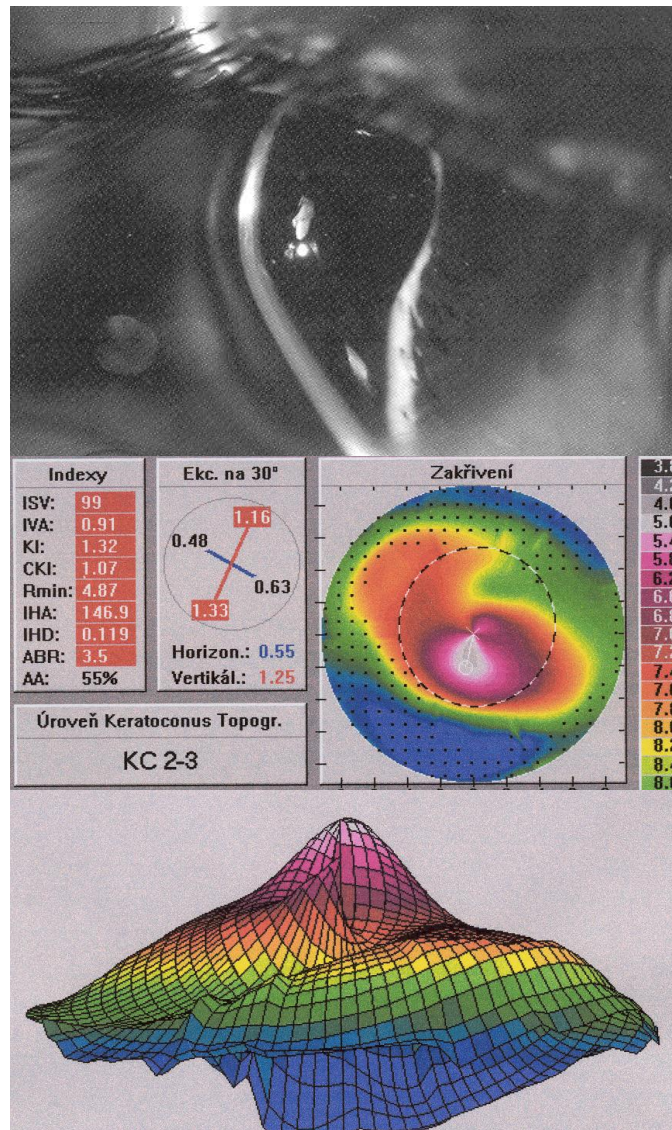
A

B

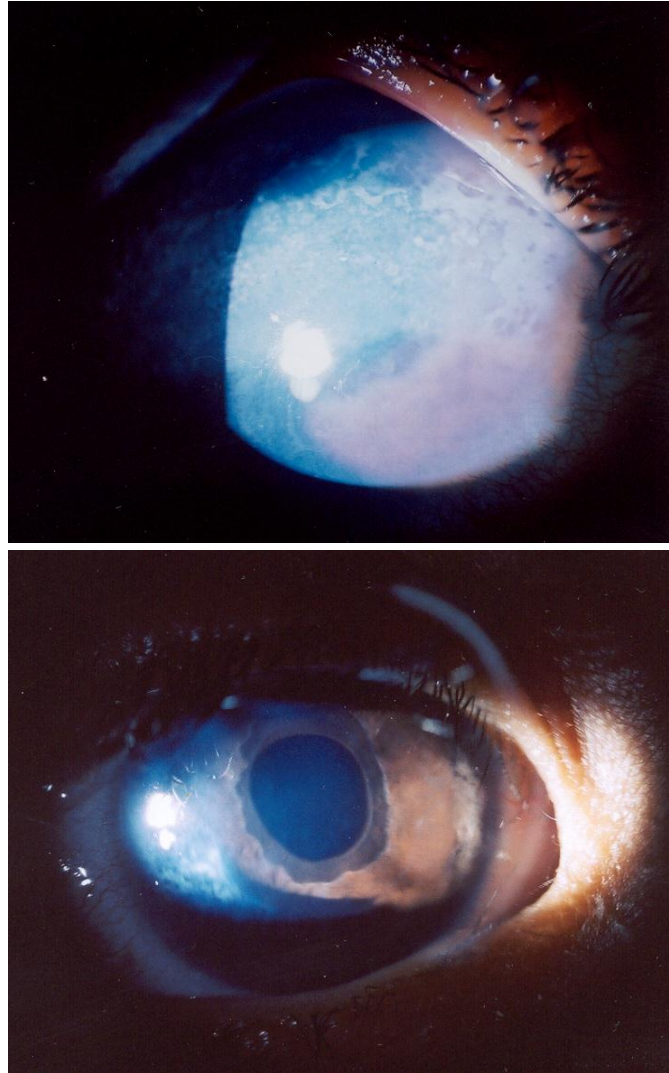
Obr. 16.3.14. Granulární dystrofie- klinický a topografický nález před (A) a 3 po PTK (B) u 15-letého chlapce. Vizus zlepšen z hodnoty 6/36 na 6/9.



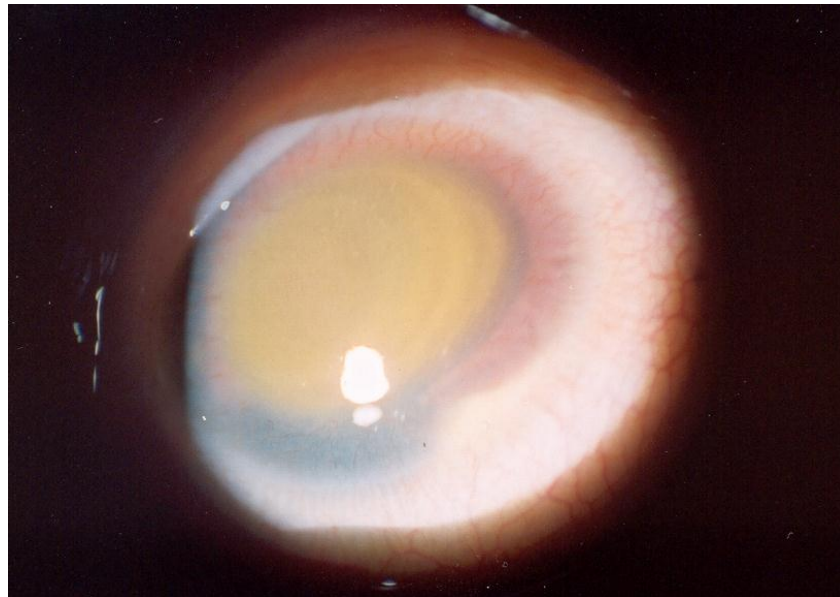
Obr. 16.3.15. Kongenitální hereditární endotelová dystrofie



Obr. 16.3.16. Keratokonus- klinický a topografický nález (14-letý chlapec)



Obr. 16.3.17. Zonulární keratopatie
u 8-letého chlapce před a 3 roky po PTK



Obr. 16.3.18. Hematokornea po těžké kontuzi oka s hemoftalmem