


Specialities of pediatric surgery




III. Year - volume

Morning activation surgery test

1. Interval of normokalemia?
2. Name the five main symptoms of local inflammation
3. Interval of normoglycemia?
4. The first aid in fractures?
5. Which is interval of normal pH of plasma?



Moaning activation surgery test conclusions



1. Interval of normokalemia?
 - 3,8 – 5,3
2. Name the five main symptoms of local inflammation
 - Calor, rubor, Tumor, Dolor, Functio laesa
3. Interval of normoglycemia?
 - 3,6 - 5,4
4. The first aid in fractures?
 - Immobilisation, transport
5. Which is interval of normal pH of plasma?
 - 7,36 – 7,44

Anamnesis



- Family anamnesis
- Personal anamnsis
- Epidemiological anamnesis
- Farmacology anamnesis
- Allergic anamnesis
- Fyziological functions
- (*Gynecological anamnesis*)

Anamnesis




- About birth
- Contact with infection
- DMO, PMR, obesity
- Psychical and social status
- Undirect anamnesis
- With child only supplementary questions
- Battery child syndrom – be careful

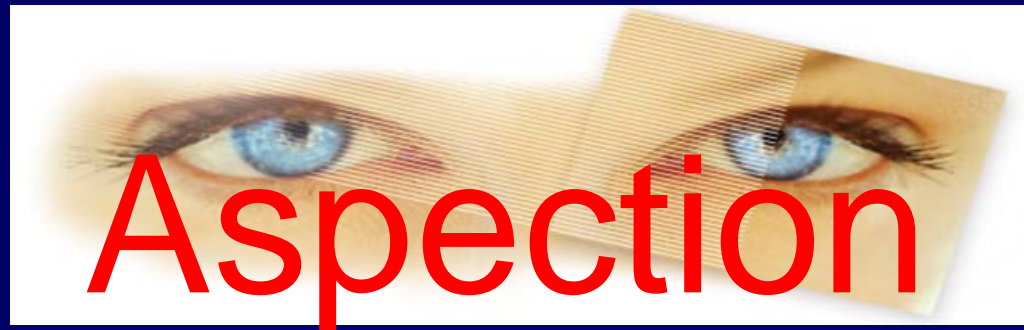- Behaviour

- spontaneous
- Fear
- Change reactions without parents

- State of consciousness

- We can weak up it from teh
- Infants don't respond to verbal irritation
- We examine reflexes (mammilingus, defense)





- Hematoma - BCS
- Head - shape, size – congenital deformities
- Chest - excavatum x carinatum
- Abdomen – ventral hernias, umbilicus

Percussion

- Head – pain, impression
- Chest
 - Hypersonorous
 - pneumothorax
 - Hyposonorous
 - Hydrothorax, infiltration
 - Cardial shadow – change of index, location
 - Kardiomyopahia, big vessels transposition
- Abdomen
 - Hypersonorous
 - Pneumoperitoneum, ileus, enteral colic - tormina
 - Hyposonorous
 - Ascites, hemoperitoneum, infiltration

Auskultation

- Neck – a. carotis communis - stenosis
- Chest
 - Pneumothorax
 - Diminished breathing or nothing
 - Hydrothorax
 - Damped breathing
 - Inflammatory or spastic phenomena
- Abdomen
 - Normal peristalsis
 - Intensive peristalsis
 - Ileus obstructive
 - Deadly silence
 - Ileus - paralysis

Palpation

- Head
 - Big fontanella, impressions
- Chest
 - Ribs fracture, lymphytic nodes
- Abdomen
 - First we examine supposed painless region
 - Blumberg, Plenies, Murphy, Tapott
- Extremities

Specialities of children

- Injuries
- Congenital defects
- Infections
- Tumours

Children specialities



Head

- Hydrocephalus – head circumference
- Craniostenosis – premature closing of big fontanella, small head circumference
- Fissures – lip, palate, mandible, jaw bone

Neck

- Persistent branchial arcus (cysts, fistulas)
- Congenital torticollis

Chest

- Pectus excavatum x carinatum
- Perstalsis in chest cavity – diaphragmatic hernia
- Congenital heart defects
- BCS multiple ribs fracture

Abdomen

- Ventral hernias
- Omfalocele – persistent yolk sac
- Gastroschisis

Limbs

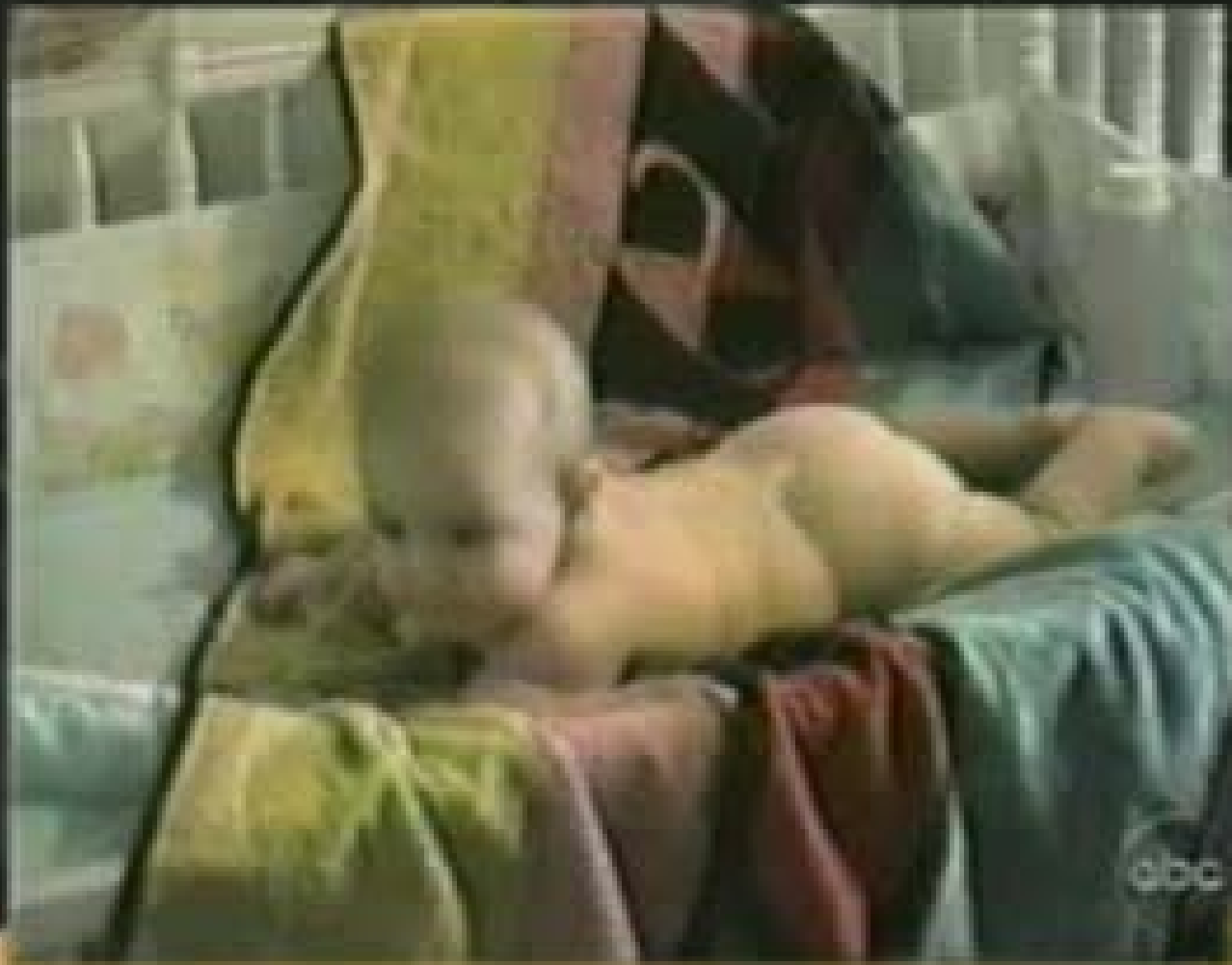- Luxatio perianularis (RU joint)
- Willow stick fracture
- Epiphyseolysis

- Good and fast healing
- Great ability of remodelation

Gastrointestinal

- Atresia of oesophagus – salivation after the birth polyhydramnion, we can't establish NG tube
- Atresia of duodenum – double bubble on X ray vomiting, polyhydramnion
- Necrotic enterocolitis
- Meconious ileus – CF
- Atresia of anus
- Burn of GIT
- Foreign body of GIT

Speciality of GIT



Respiratory system

- Cystic fibrosis
- Bronchopulmonary dysplasia (33. w.g.)
- Laryngitis
- Foreign bodies

Excretory system

- Hydronephrosis
- Wilms tumour
- VUR
- Hypospadias
- Stenosis of urethra
- Testicular retention

Excretory system



Nervous system

- Hydrocephalus
- Meningomyelocele
- Tumours – gliomas
- Craniostenosis
- Child cerebral palsy
- Light cerebral dysfunction

Musculoskeletal system

- Coxa vara
- Aseptic necrosis of femoral head
- Pes equinovarus
- Morbus Oosgod – Schlatter
- Spatic contractures
- Cysts and tumours (Ewing)

Diagnostic test

Case 1

- Bend over
 - Subfebrilia
 - Emesis
 - Pain in right hypogastric region
 - Anamnesis cca 3 hours
 - Sonografic examination negative
 - CRP 12
 - WBC 6,4
-
- Appendicitis acuta

Case 2

- Age 3 years
 - Diarrhoea with blood
 - Abdoinal bloating
 - Emesis
 - Intensive peristalsis
 - Sonografic examination positive
-
- Inususception

Case 3

- Header
 - 4 s unconsciousness
 - Somnolence
 - Emesis
 - Headache
 - X ray negative
 - CT positive
-
- Epidural hematoma

Case 4

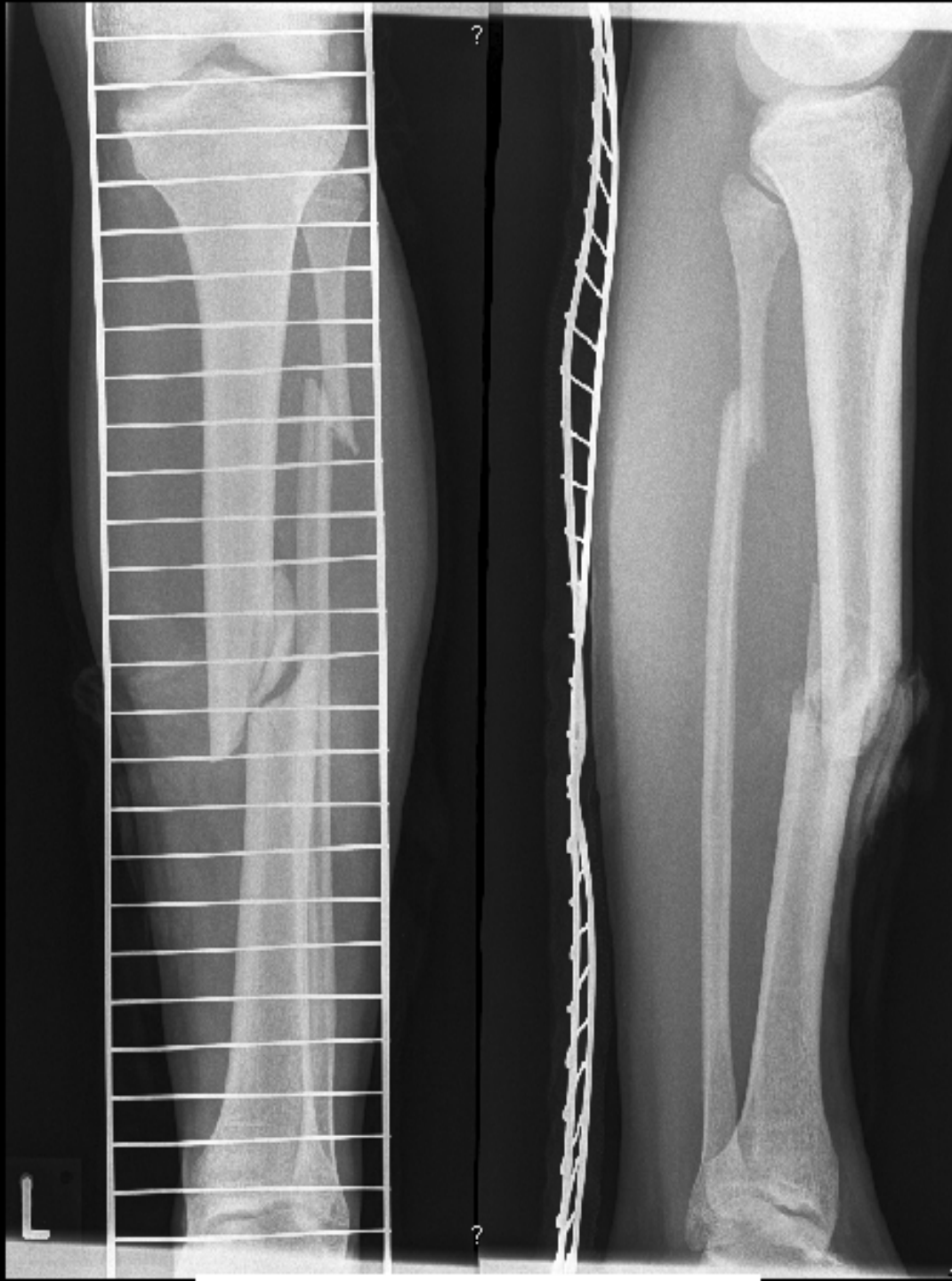- Fall from a tree
- Left side of body impact
- Urina without erythrocytes
- Pallor
- Pain of left shoulder
- Ultrasonography positive
- CT positive
- RBC decline


- Lienal ruptura

Radiodiagnostic test

ID:078500
Kvas Michal
Narozen:1989-03-24
Datum:2005-01-02
Cas:18:39:17
No.1

1




Q: 80% 

FN Brno -Detska nemocnice
ADC_5146

C: 2583
W: 2635

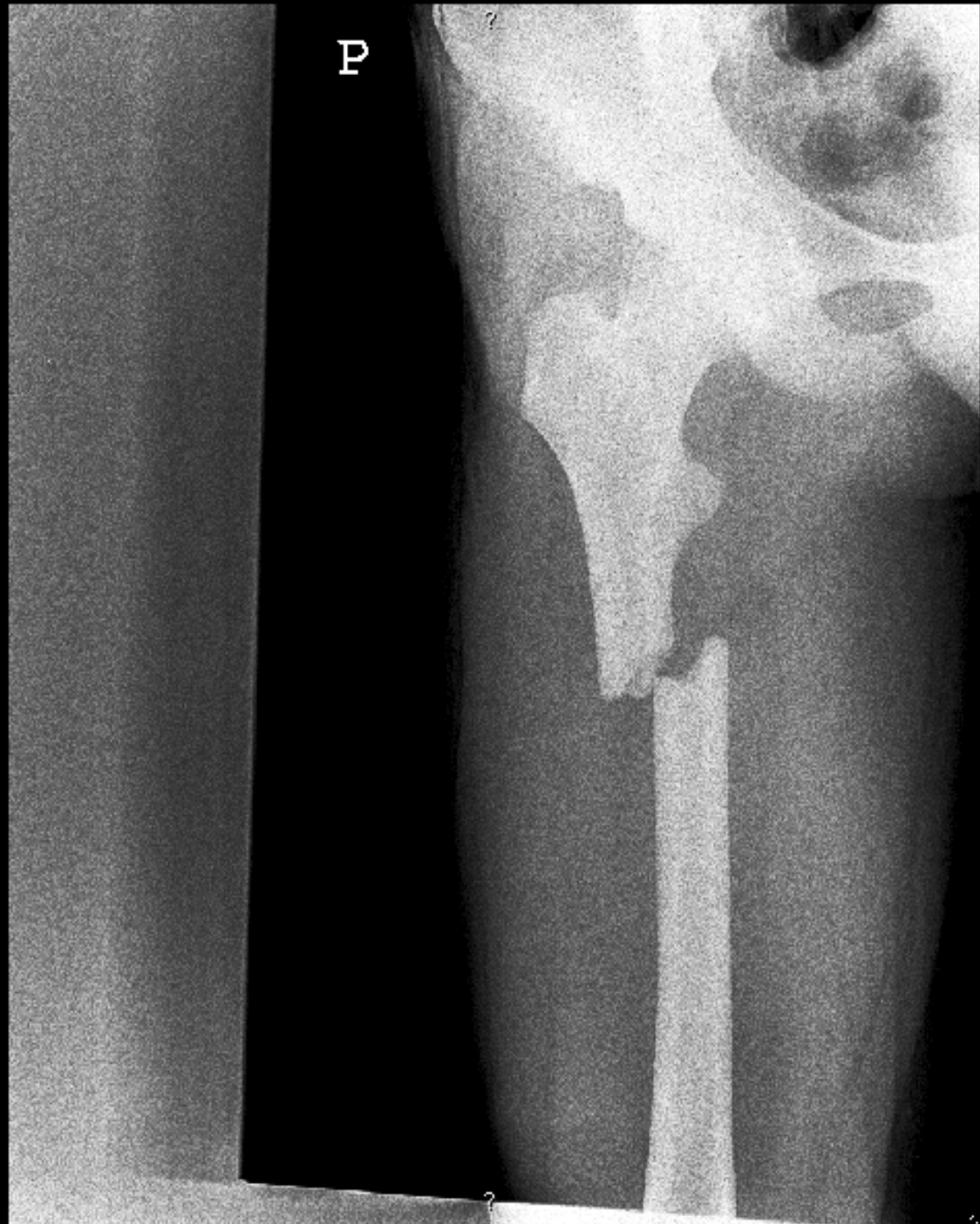ID:880310/4464
Lechner Jan
Narozen:1988-03-10
Datum:2005-09-12
Cas:08:48:22
No.1

P

Q: 80% 


FN Brno -Detska nemocnice
ADC_5146

2



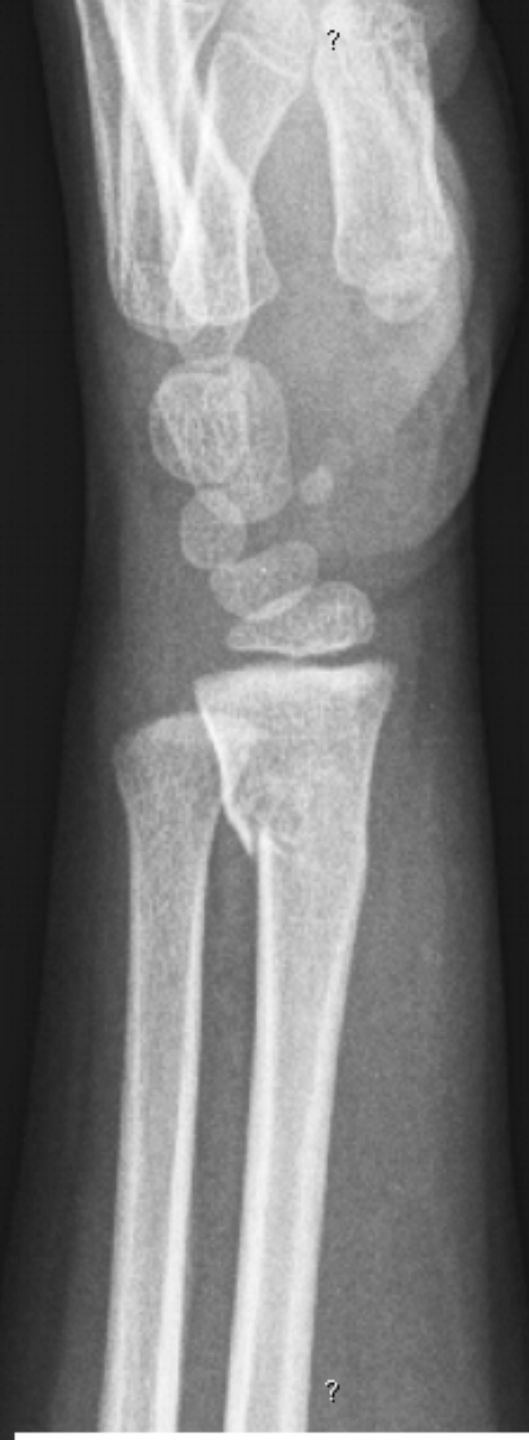C: 1952
W: 1206

ID:007939
Tenora Karel
Narozen:1998-04-17
Datum:2005-05-14
Cas:17:25:20
No.1

Co: 80% 


FN Brno -Detska nemocnice
ADC_5146

3

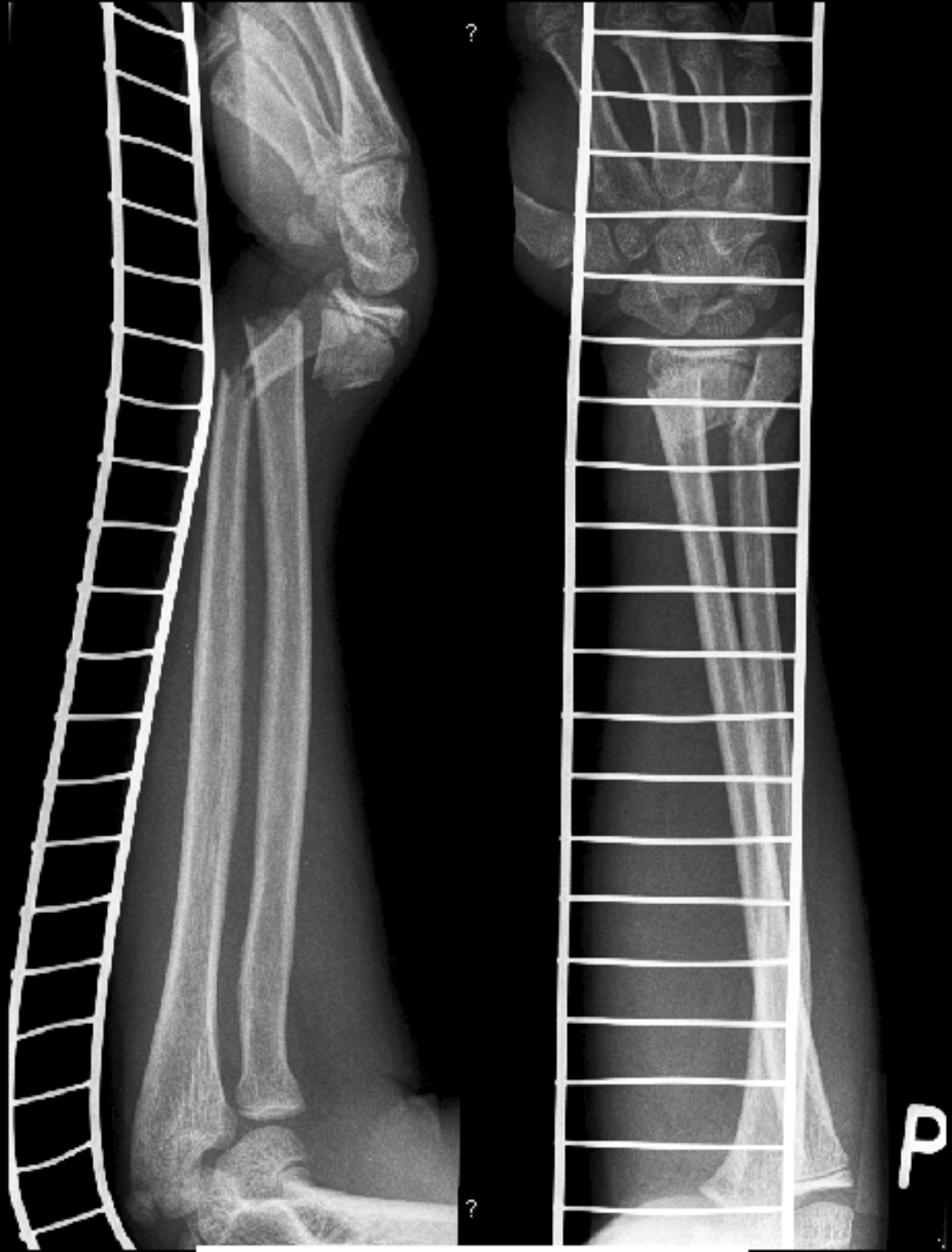

C: 3572
W: 1198

ID: 920504/4222
Vodicka Jiri
Narozen: 1992-05-04
Datum: 2005-09-02
Cas: 19:01:11
No.1

? Q: 80% 
FN Brno -Detska nemocnice
ADC_5146

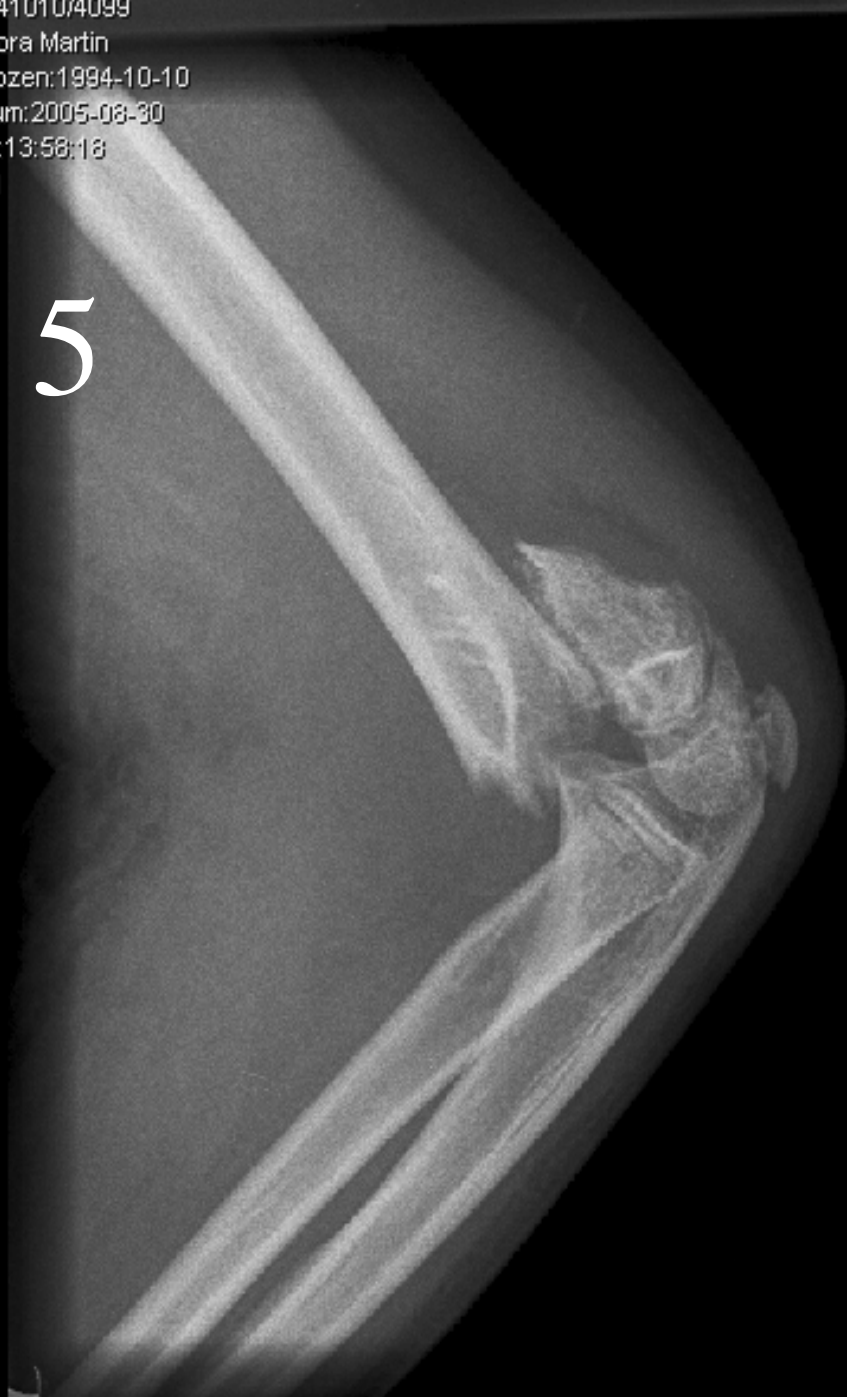4




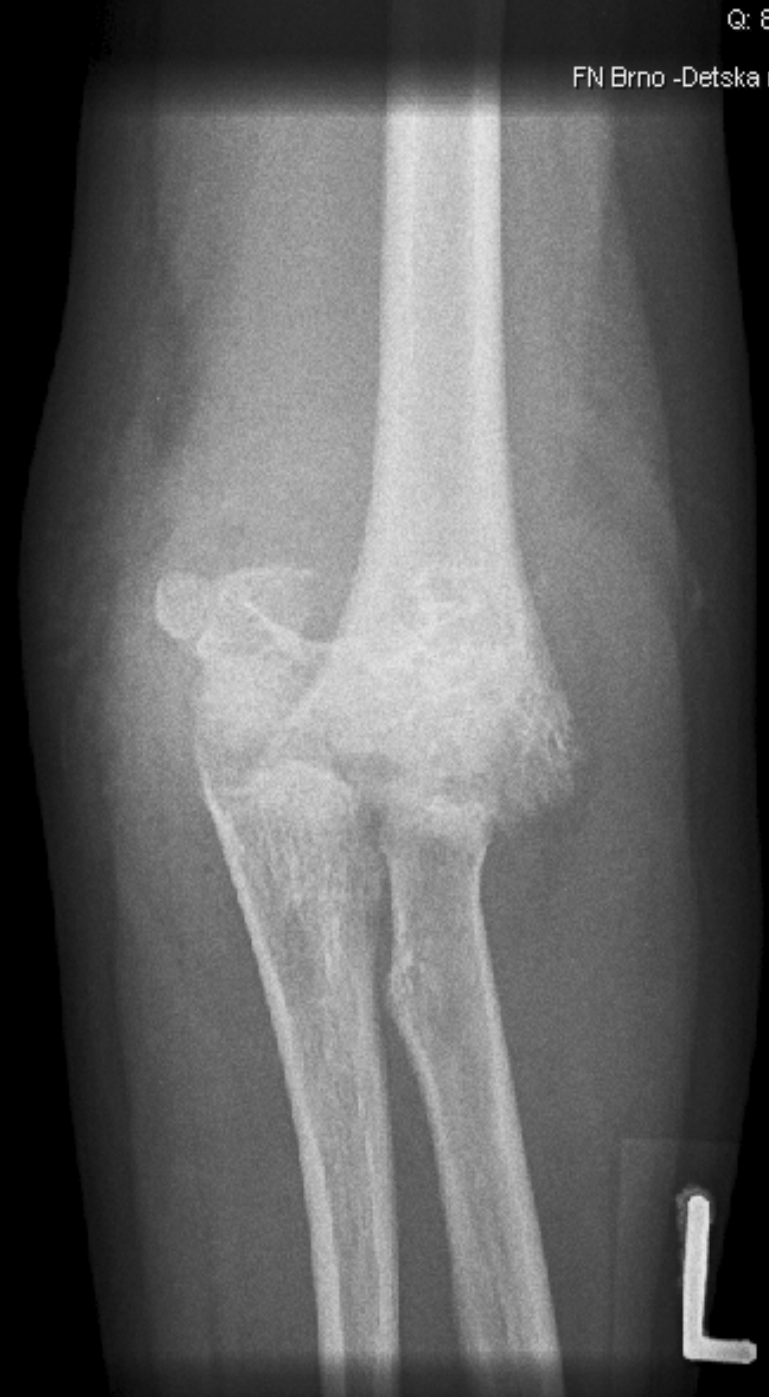C: 3405
W: 1047

ID:941010/4099
Fasora Martin
Narozen:1994-10-10
Datum:2005-03-30
Cas:13:58:18
No.1

5



Q: 80% 
FN Brno -Detska nemocnice
ADC_5146



C: 2887
W: 1769

ID:083849
Zarychtova Simona
Narozen:1999-12-23
Datum:2005-03-07
Cas:12:28:17
No.1

6



?

Q: 80%

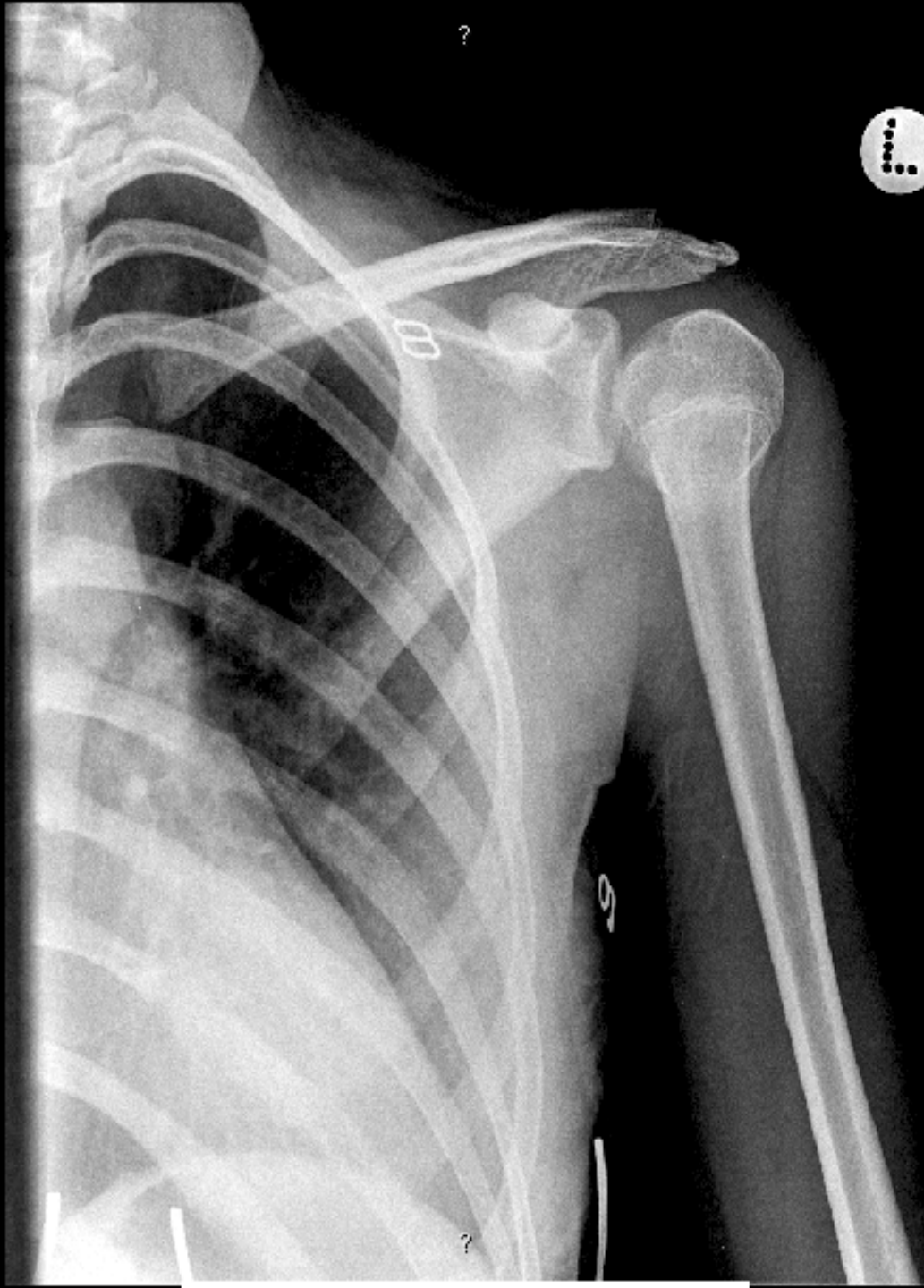

FH Brno -Detska nemocnice
ADC_51xx

C: 2780
W: 1895

ID:094973
Zemanova Veronika
Narozen:1990-09-24
Datum:2005-07-20
Cas:21:56:01
No.1

7



Q: 80%



FN Brno -Detska nemocnice
ADC_5146



C: 2890
W: 1088

Thaisz Merlin
ID:082185
DoB:2004-04-01
2005-02-14
23:41:45
No.15

AH

Q: 90%

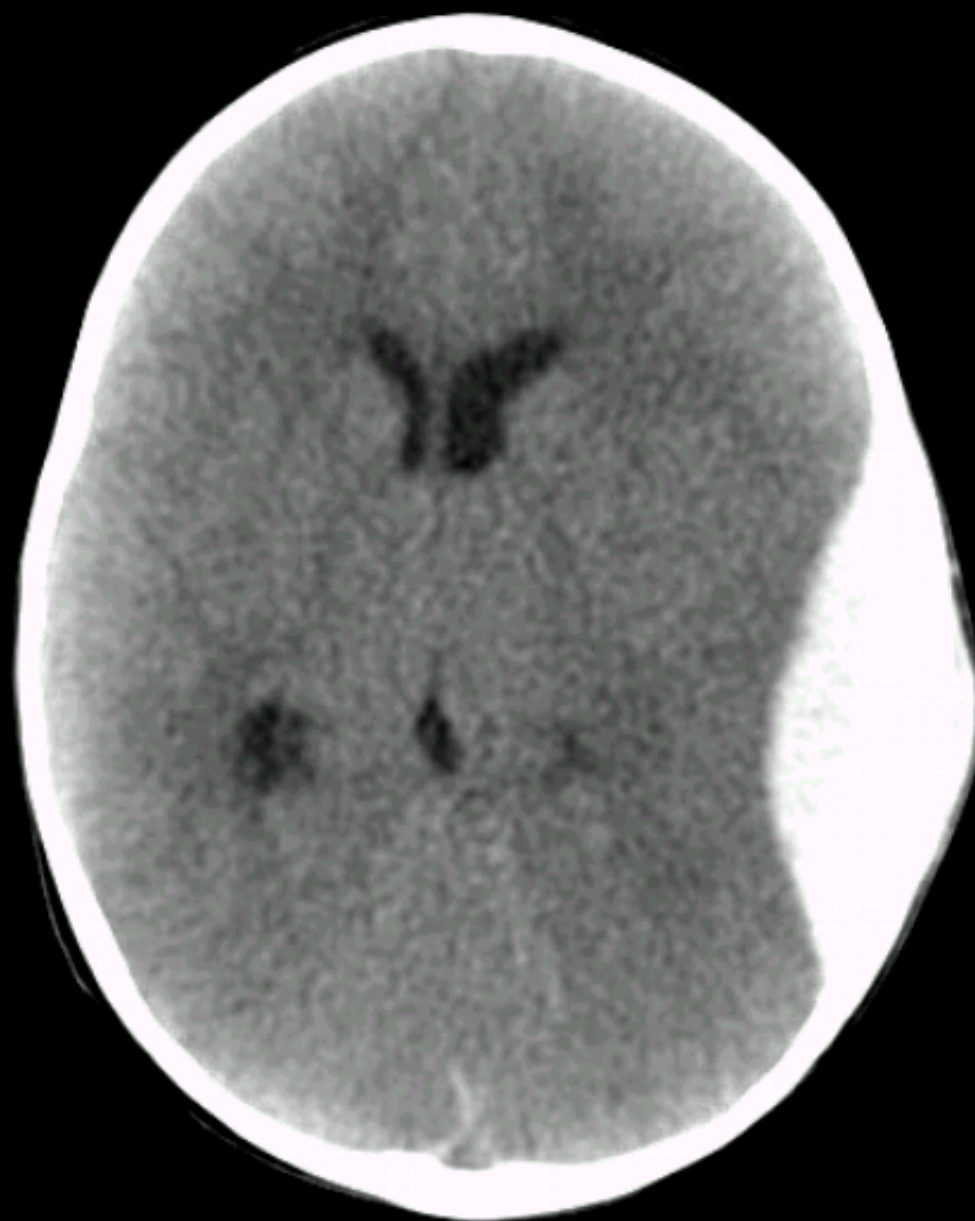

Fak. detska nemocnice
SOMATOM PLUS 4

8

R

L




RM
GT:-2
SP:350
SL:5
CM:

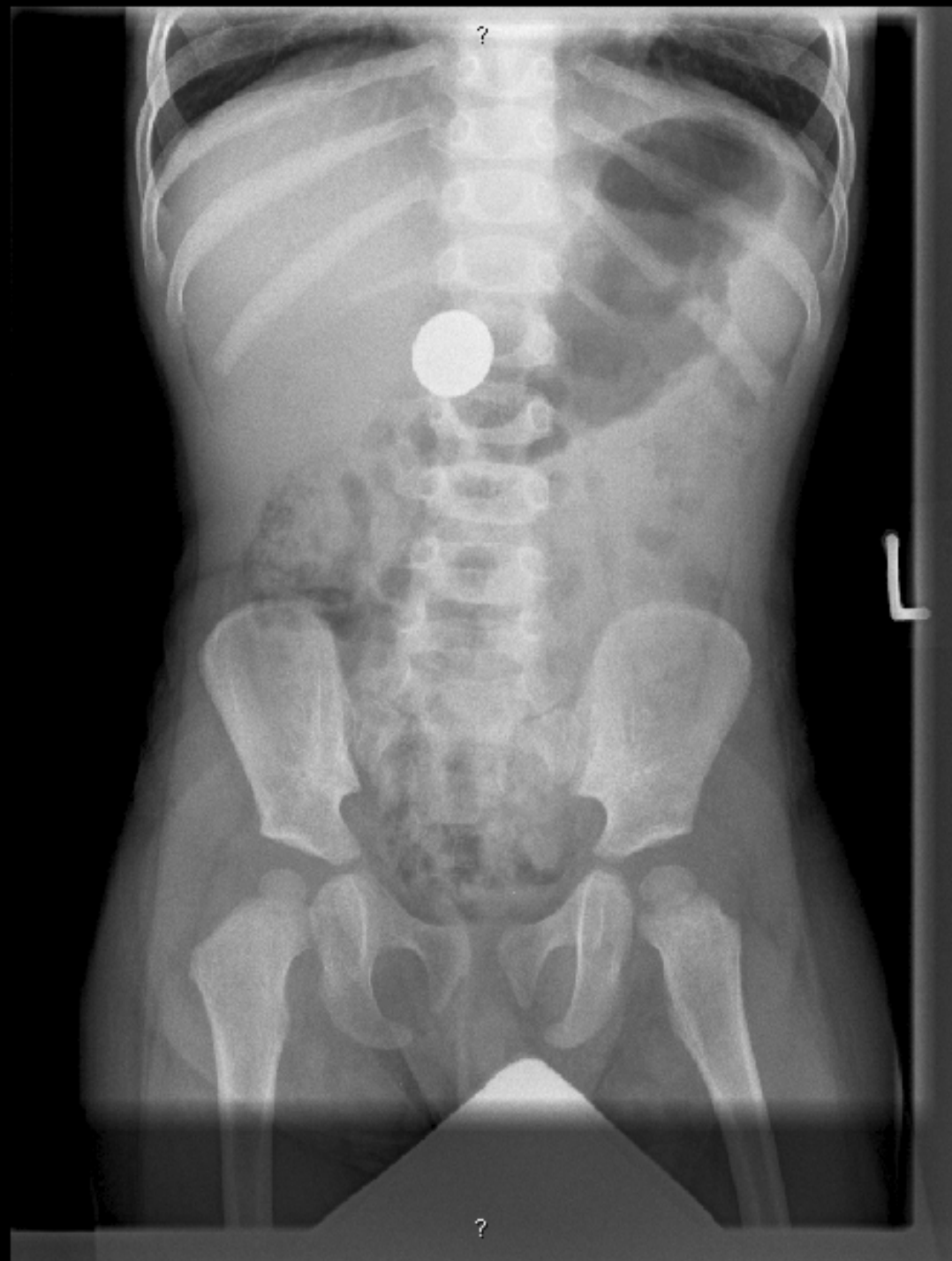PF

C: 35
W: 80

ID:081582
Huser Tomas
Narozen:2003-06-03
Datum:2005-02-11
Cas:09:31:18
No.1

Q: 80% 
FN Brno -Detska nemocnice
ADC_5146

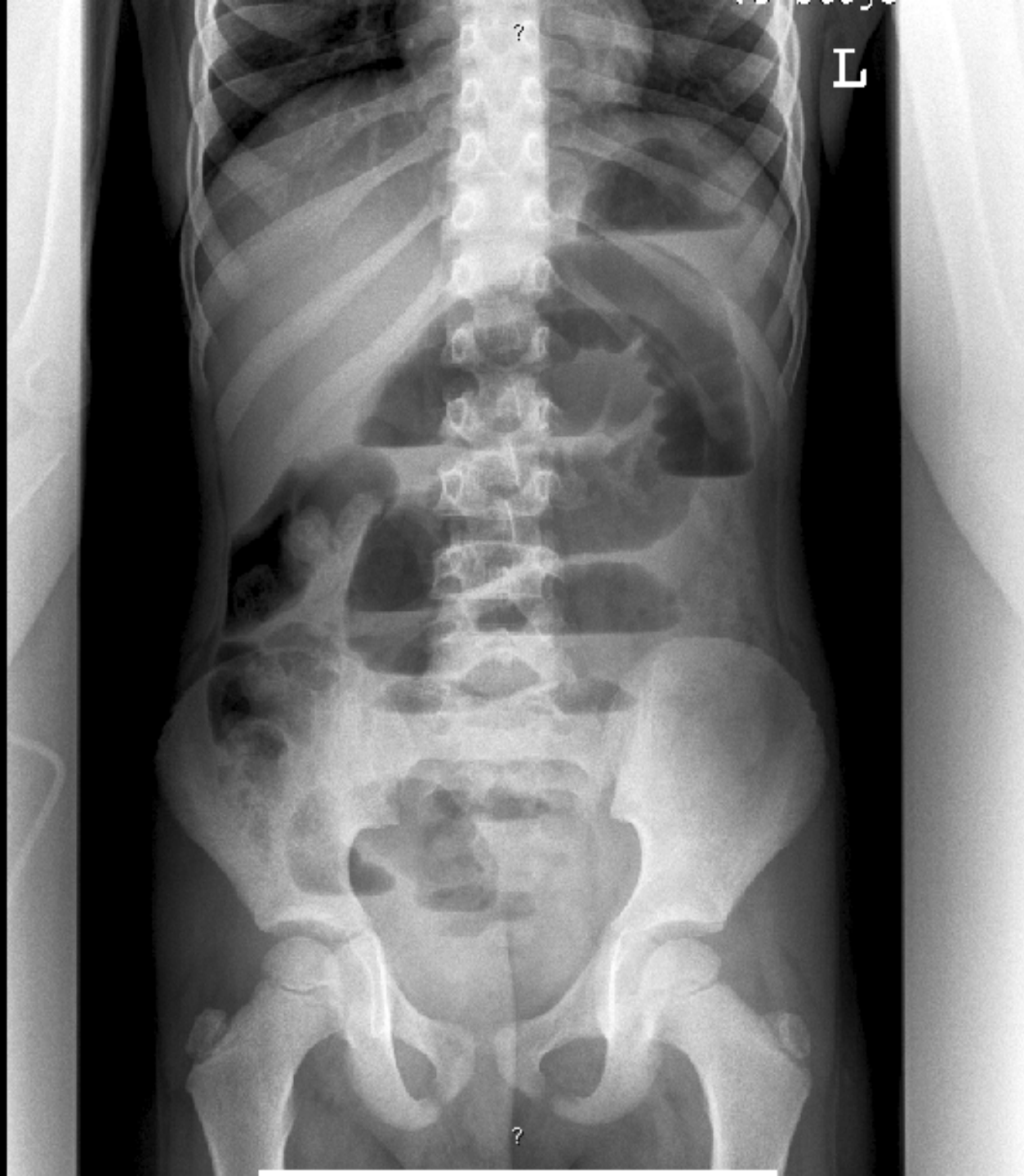
9




C: 2968
W: 1625

ID:002433
Vojta Jiri
Narozen:1999-11-30
Datum:2005-04-17
Cas:08:59:46
No.1

10




Q: 80% 
FN Brno -Detska nemocnice
ADC_5146

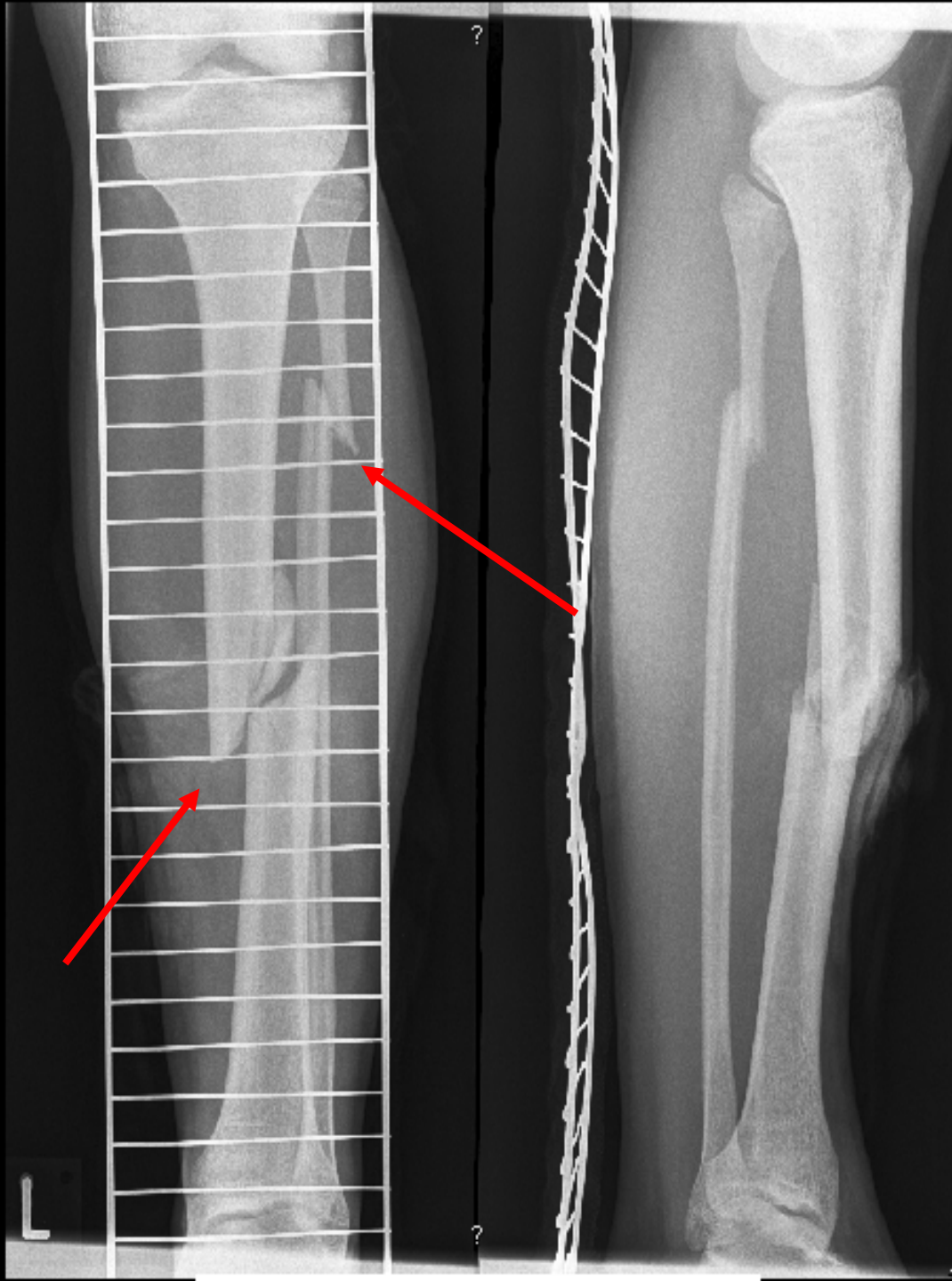
C: 2426
W: 1865

Radiodiagnostic test conclusions

ID:078500
Kvas Michal
Narozen:1989-03-24
Datum:2005-01-02
Cas:18:39:17
No.1

Q: 80% 
FN Brno -Detska nemocnice
ADC_5146

1



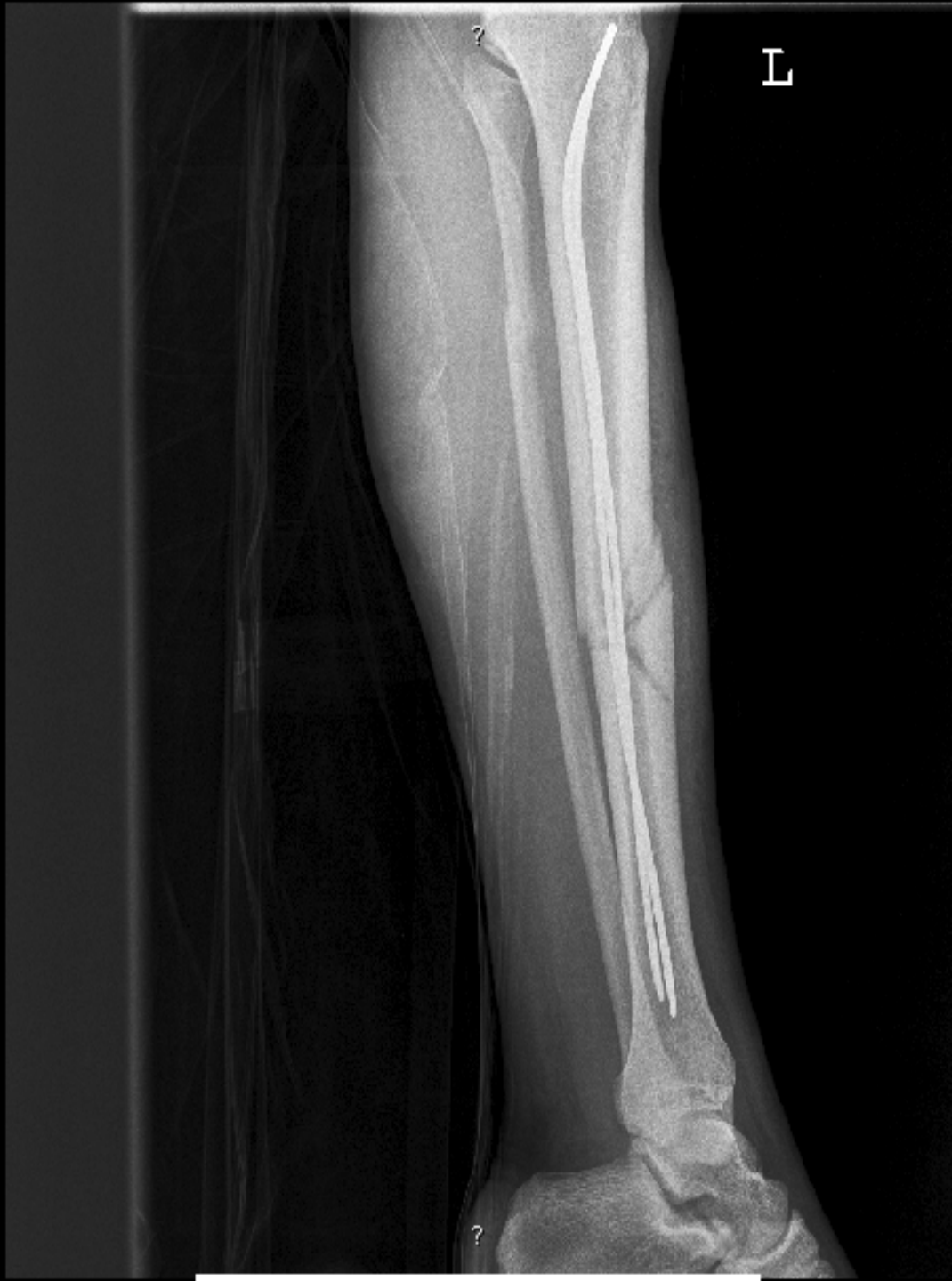C: 2583
W: 2635

ID:078500
Kvas Michal
Narozen:1989-03-24
Datum:2005-01-04
Cas:08:51:47
No.1

Q: 80%



FN Brno -Detska nemocnice
ADC_5146

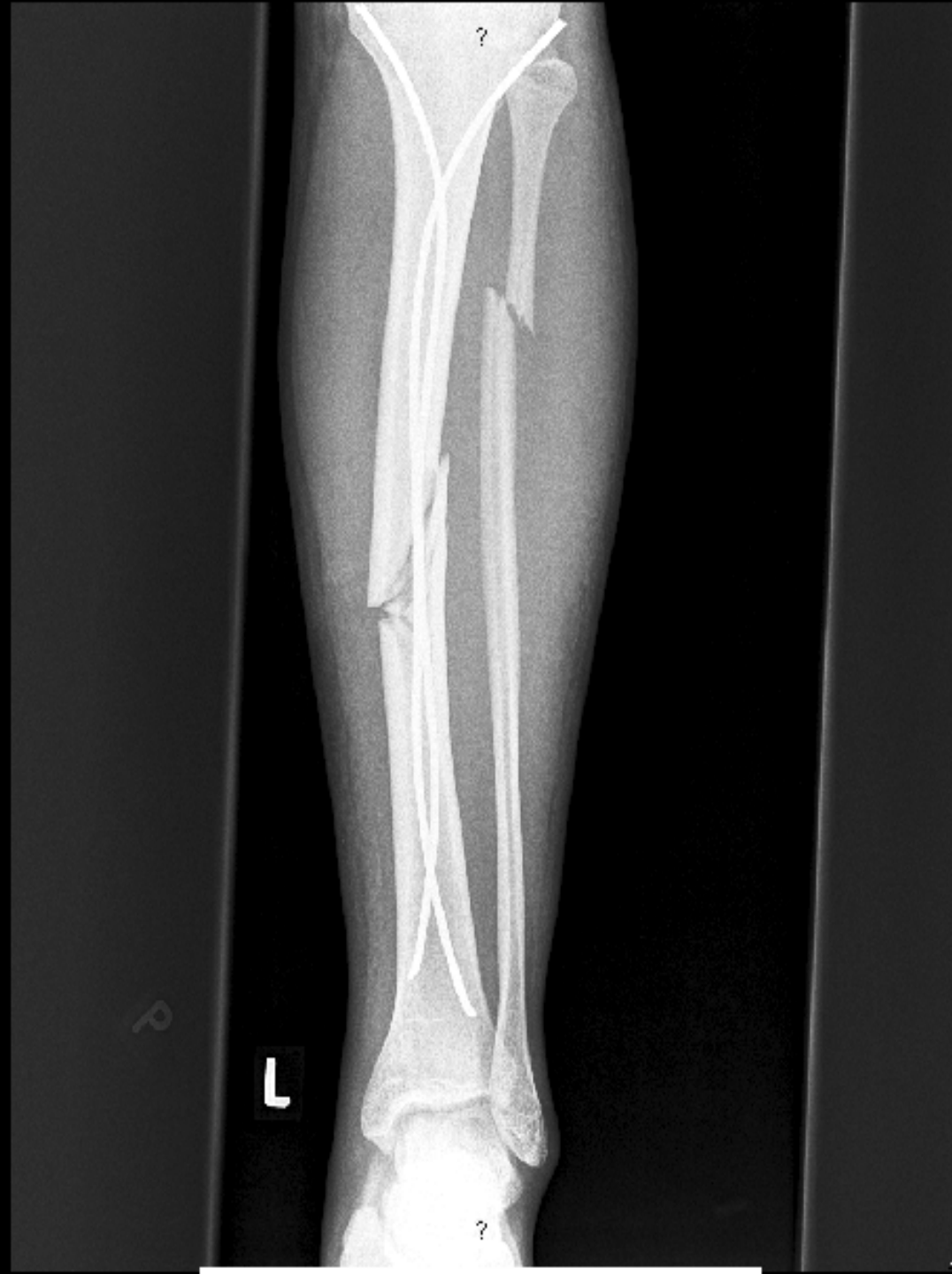

C: 2660
W: 2061

ID:078500
Kvas Michal
Narozen:1989-03-24
Datum:2005-01-04
Cas:08:52:11
No.1


Q: 80% 

FN Brno -Detska nemocnice
ADC_5146



C: 2745
W: 1684

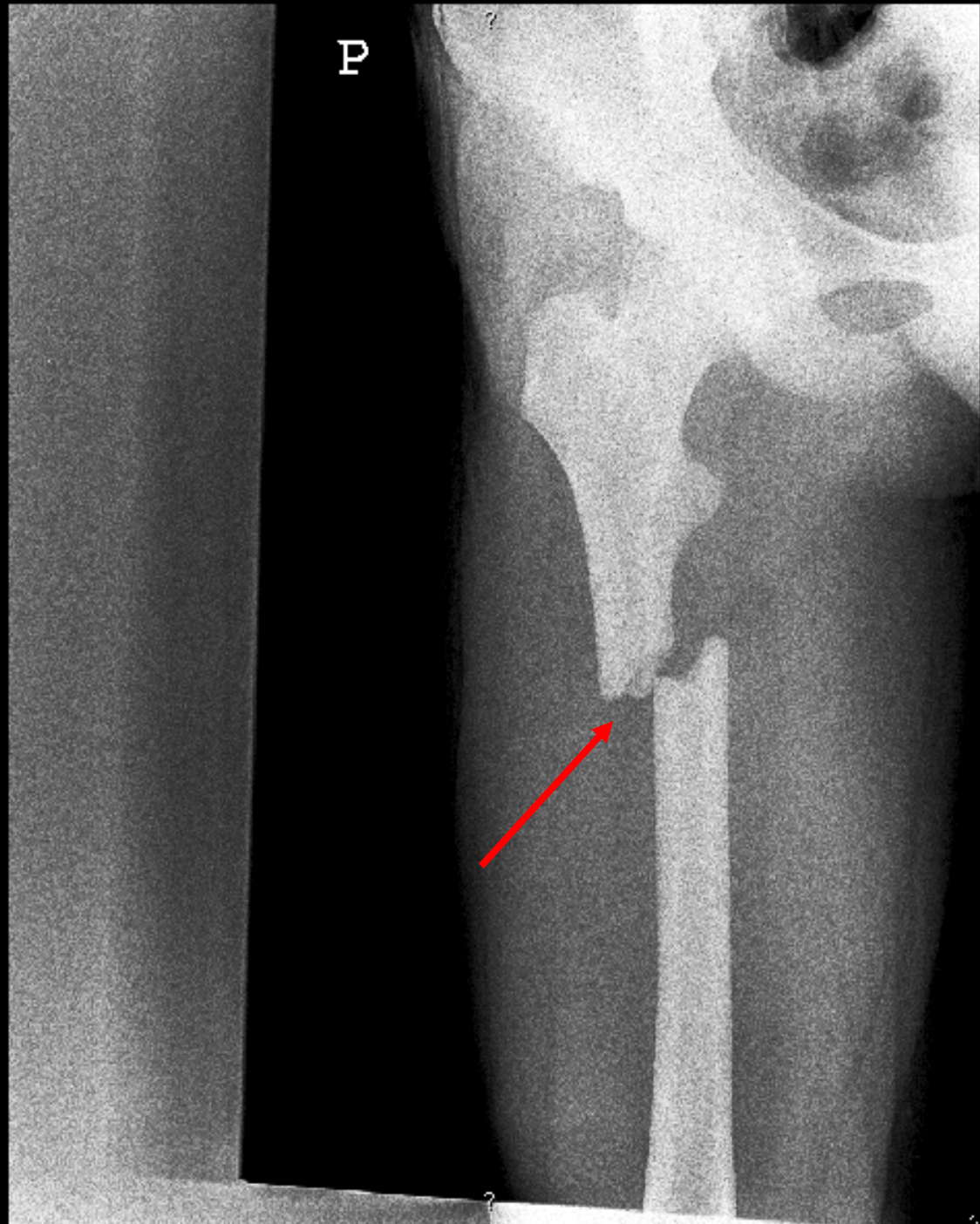
ID:880310/4464
Lechner Jan
Narozen:1988-03-10
Datum:2005-09-12
Cas:08:48:22
No.1

Q: 80% 

FN Brno -Detska nemocnice
ADC_5146

P

2

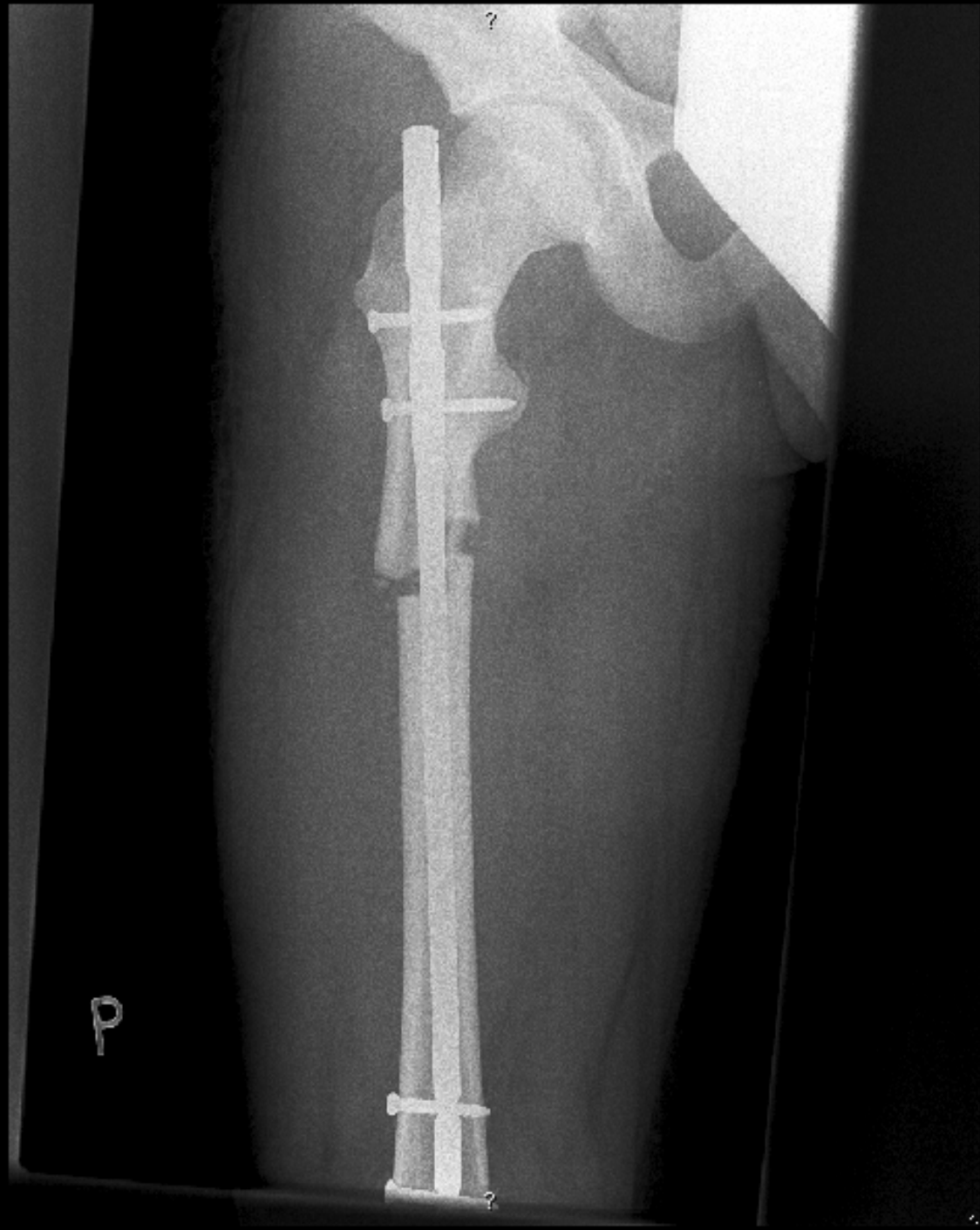

C: 1952
W: 1206

ID:880310/4464
Lechner Jan
Narozen:1988-03-10
Datum:2005-09-14
Cas:08:11:16
No.1

Q: 80% 

FN Brno -Detska nemocnice
ADC_5146



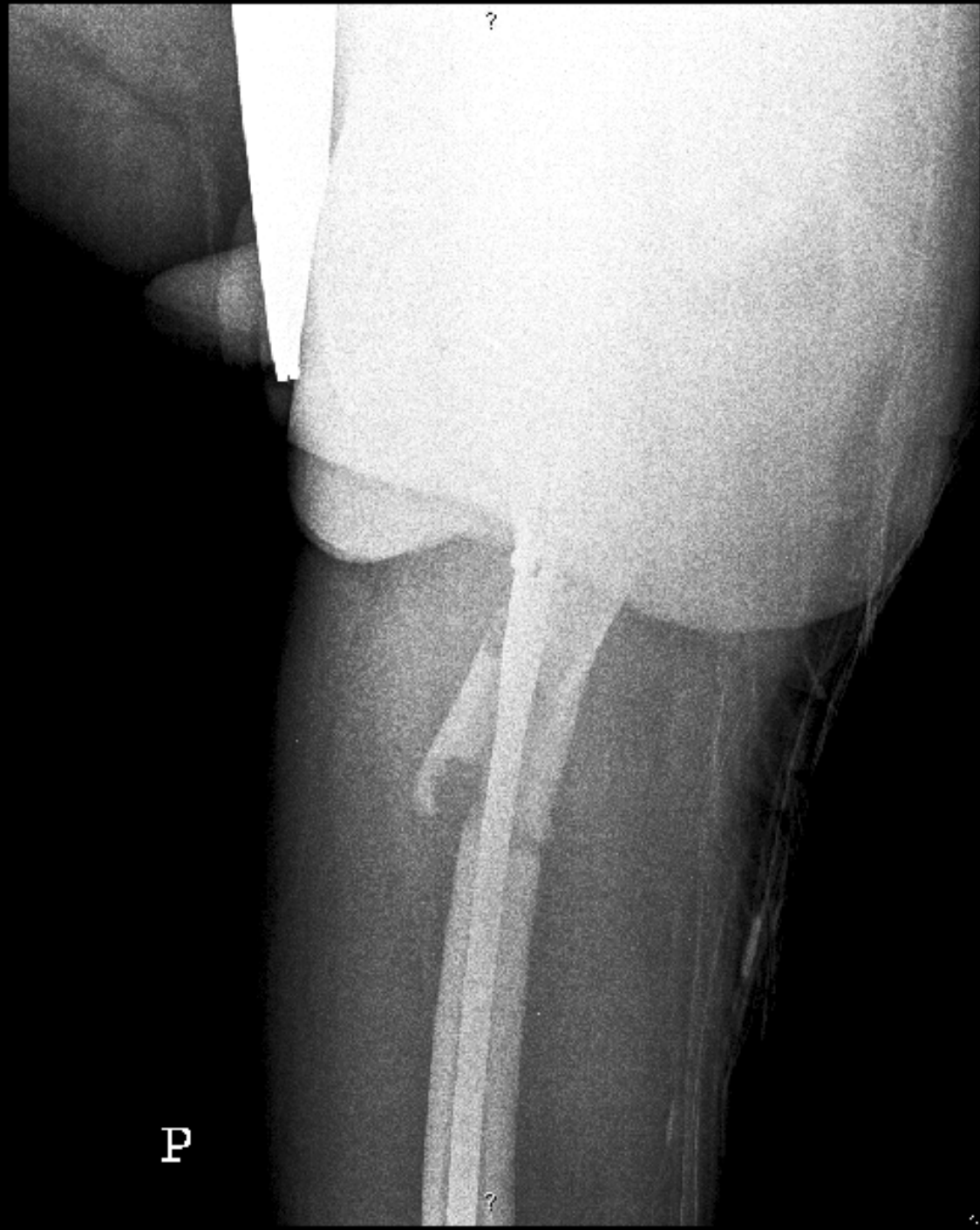C: 2450
W: 1830

ID:880310/4464
Lechner Jan
Narozen:1988-03-10
Datum:2005-09-14
Cas:08:15:30
No.1

Q: 80%




FN Brno -Detska nemocnice
ADC_5146



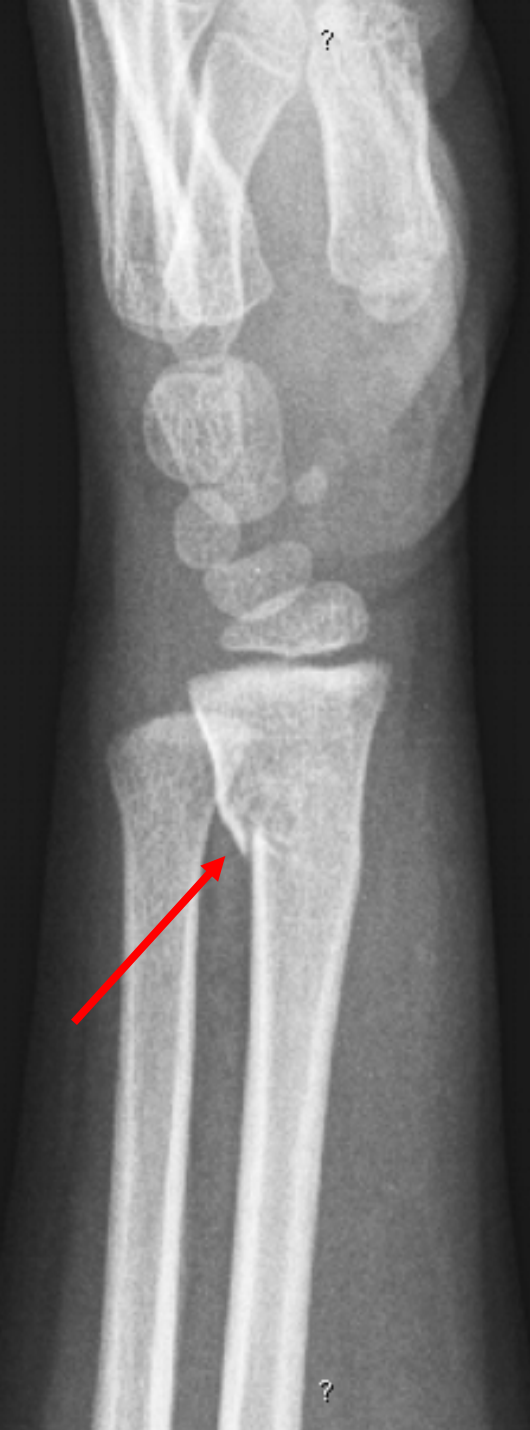P

C: 2375
W: 1252

ID:007939
Tenora Karel
Narozen:1998-04-17
Datum:2005-05-14
Cas:17:25:20
No.1


Co: 80% 
FN Brno -Detska nemocnice
ADC_5146

3

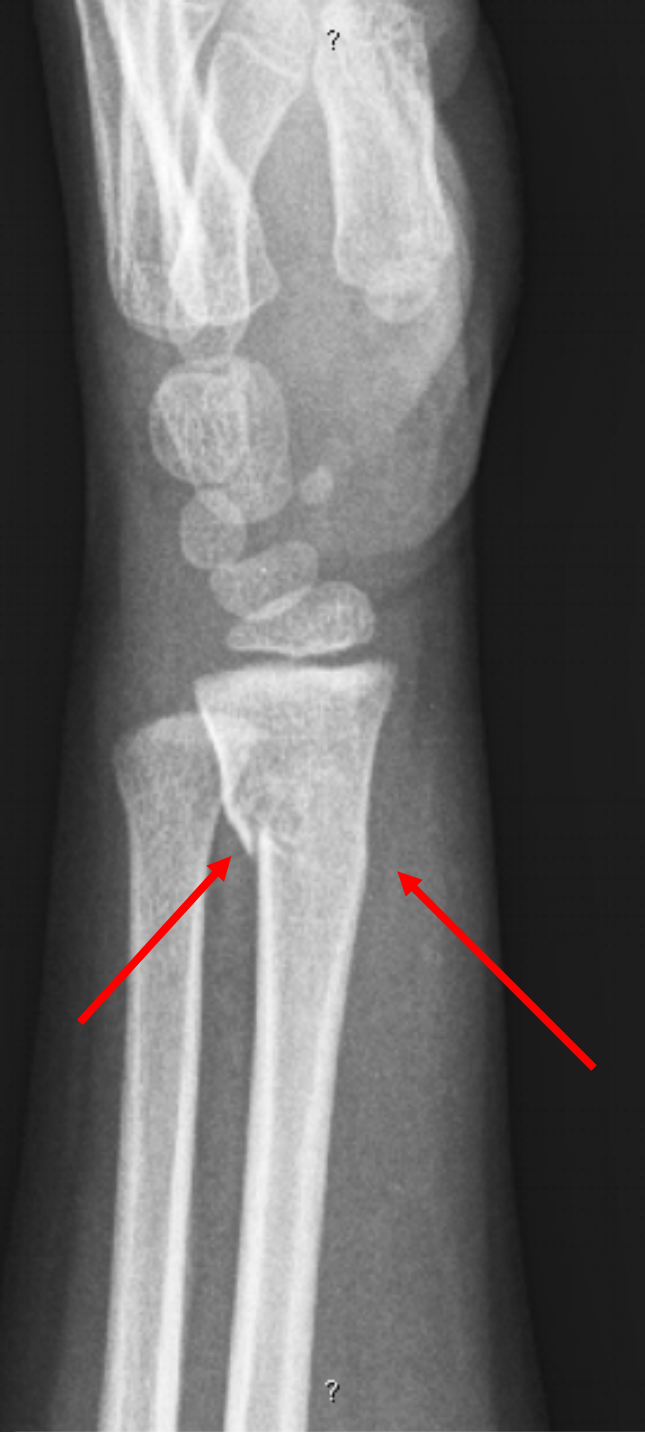

C: 3572
W: 1198

ID:007939
Tenora Karel
Narozen:1998-04-17
Datum:2005-05-14
Cas:17:25:20
No.1


Co: 80% 

FN Brno -Detska nemocnice
ADC_5146

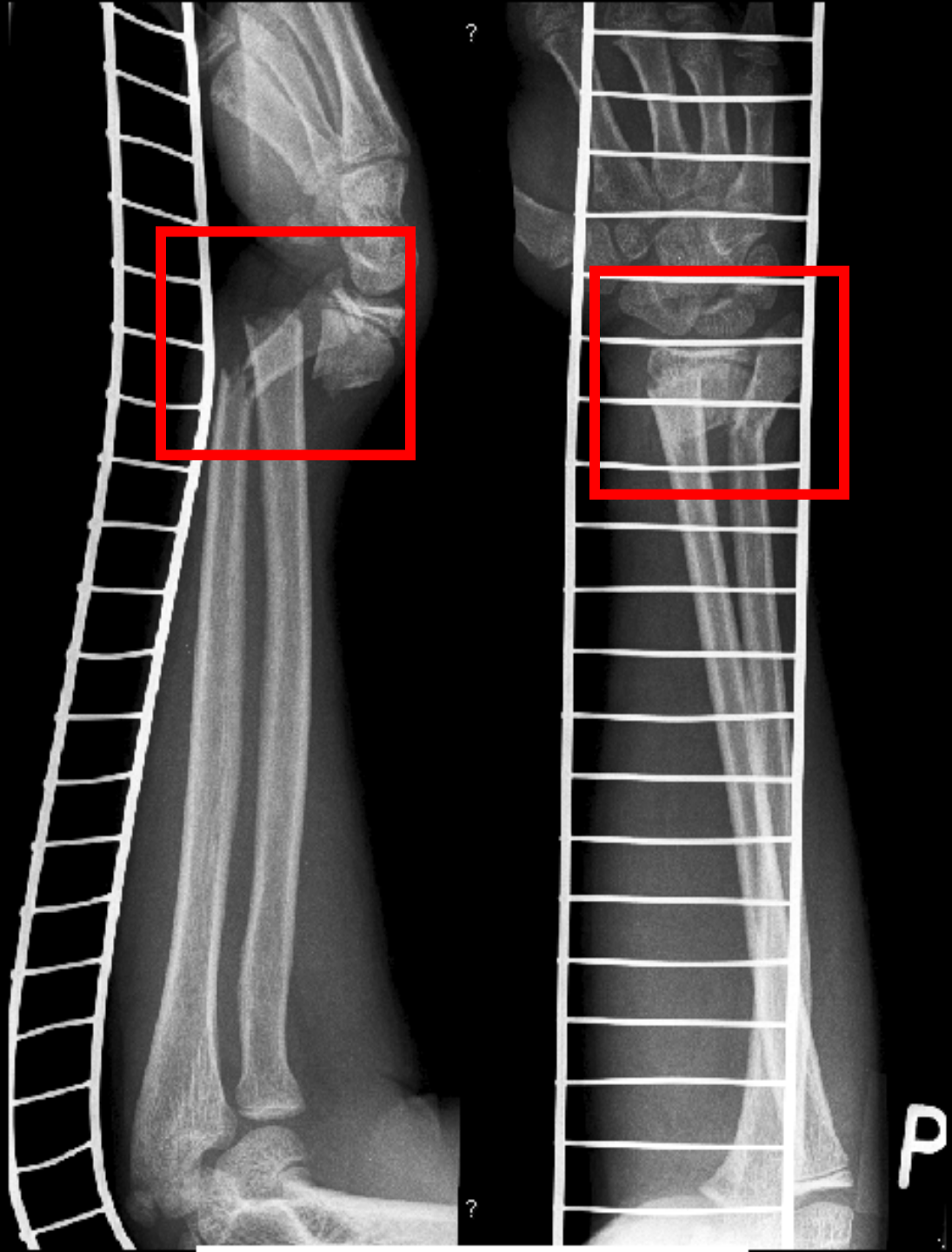


C: 3572
W: 1198

ID: 920504/4222
Vodicka Jiri
Narozen: 1992-05-04
Datum: 2005-09-02
Cas: 19:01:11
No.1

? Q: 80% 
FN Brno -Detska nemocnice
ADC_5146

4



C: 3405
W: 1047

ID: 920504/4222
Vodicka Jiri
Narozen: 1992-05-04
Datum: 2005-09-04
Cas: 08:55:17
No.1

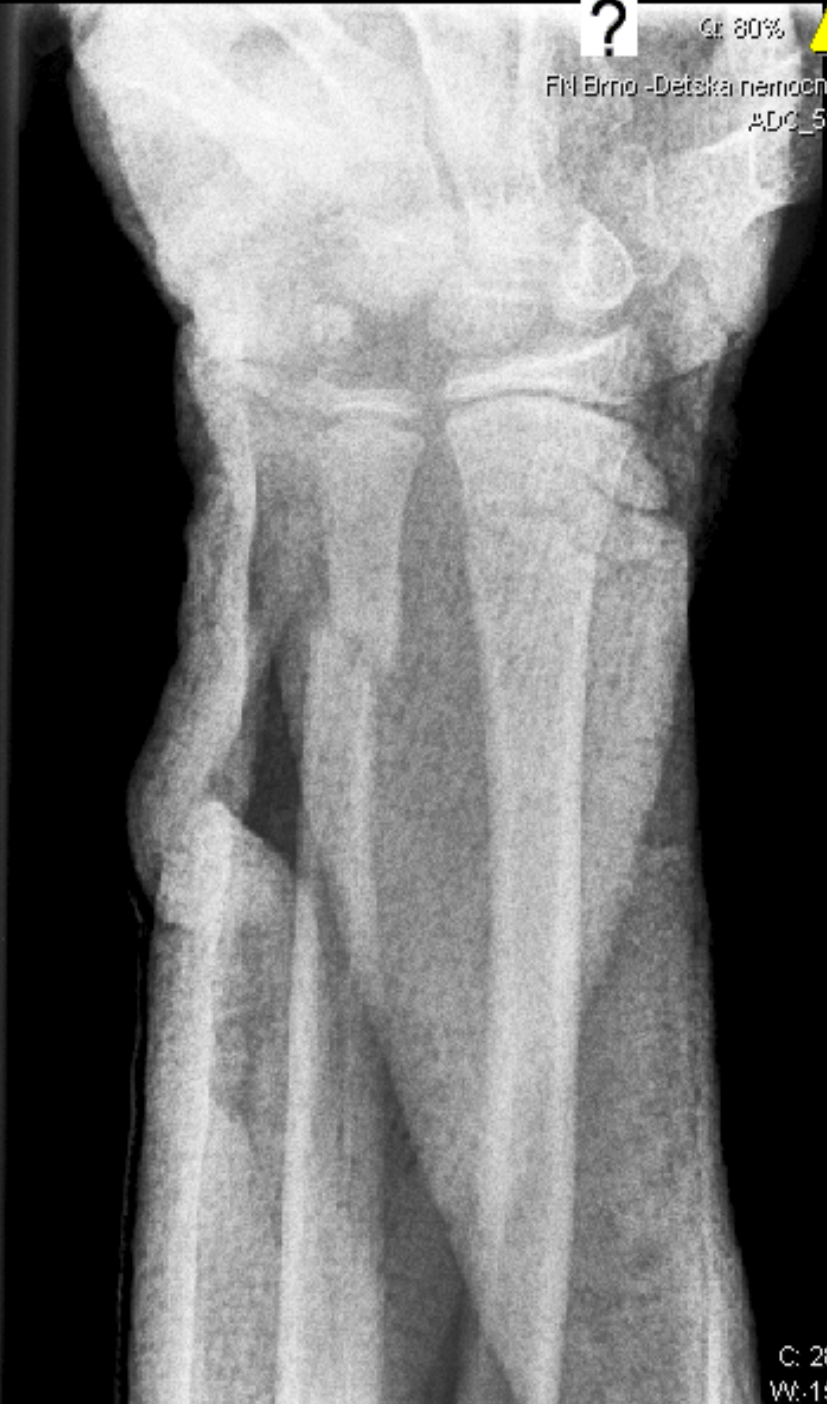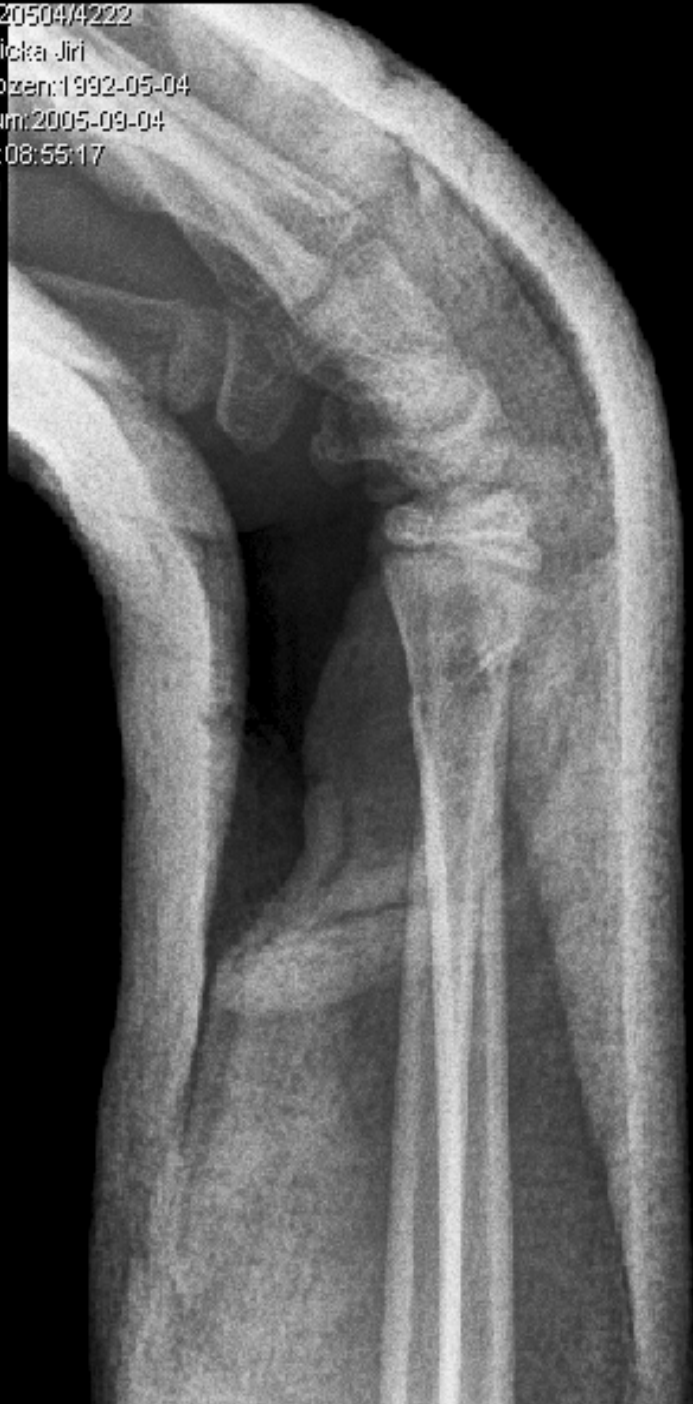P

?

Gr 80%



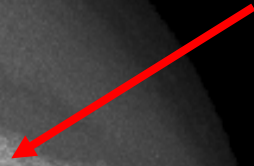
FH Brno - Detska nemocnice
ADC_5146




C: 2800
W: 1595

ID:941010/4099
Fasora Martin
Narozen:1994-10-10
Datum:2005-03-30
Cas:13:58:18
No.1

5

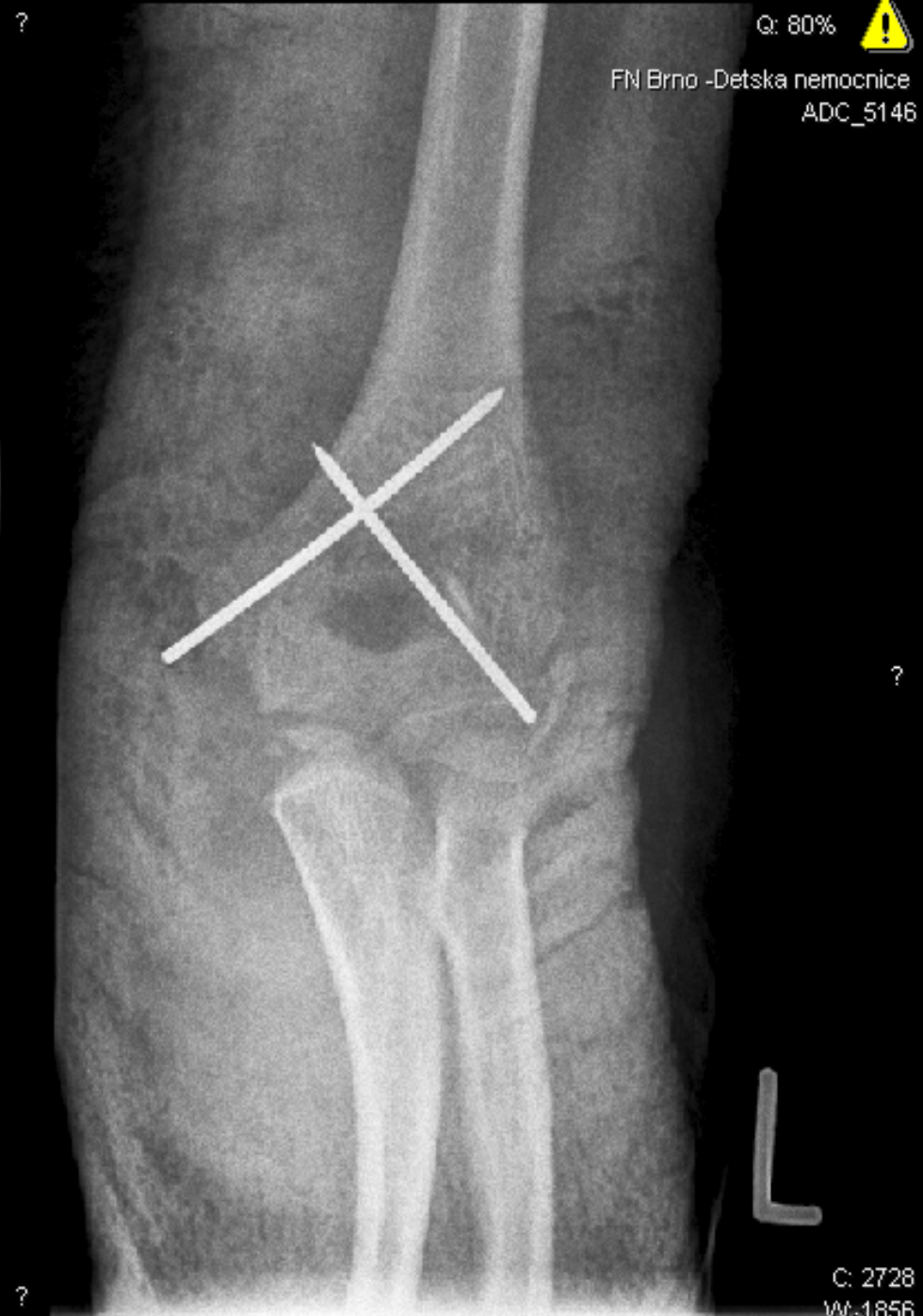
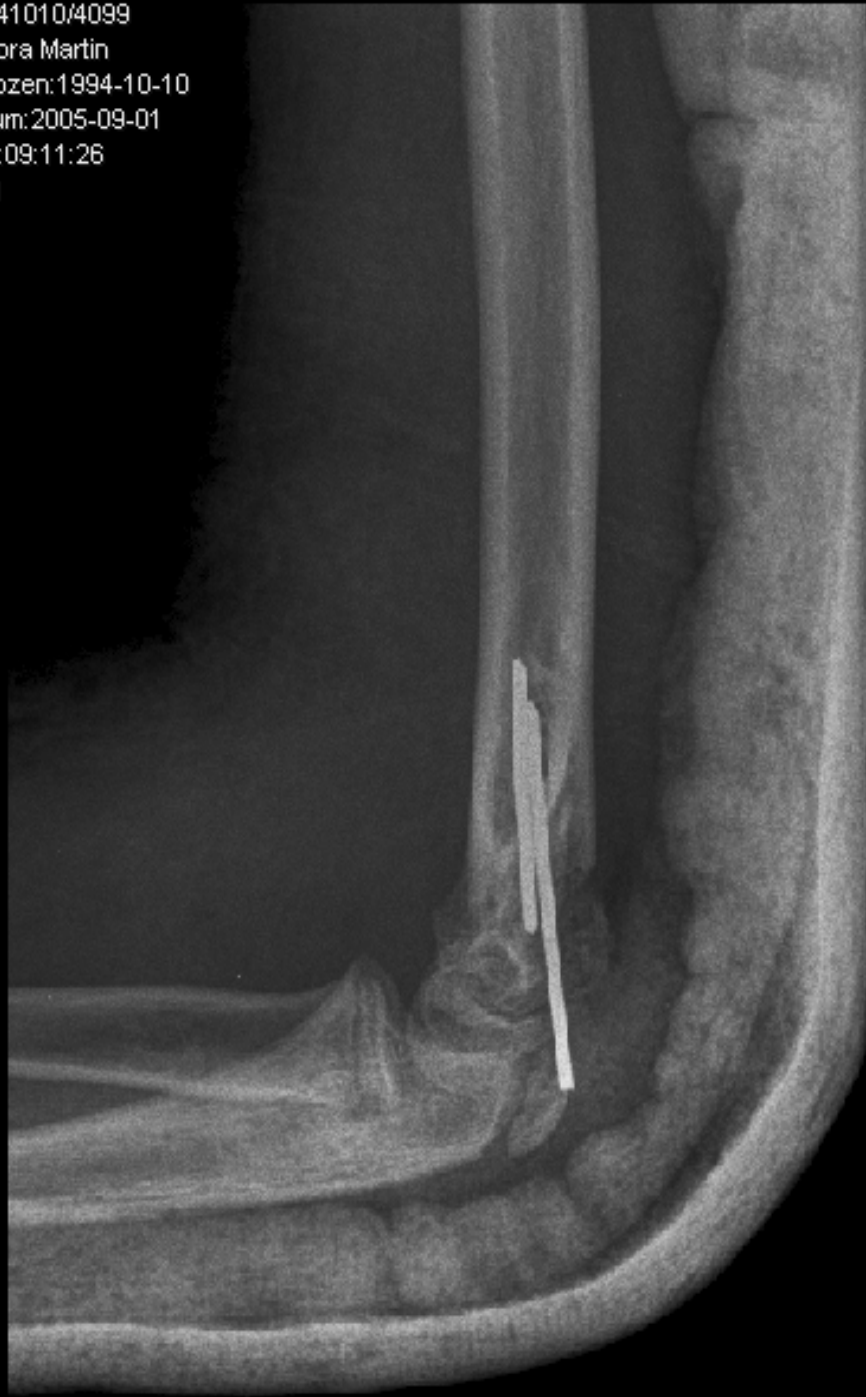

Q: 80% 
FN Brno -Detska nemocnice
ADC_5146



C: 2887
W: 1769

ID:941010/4099
Fasora Martin
Narozen:1994-10-10
Datum:2005-09-01
Cas:09:11:26
No.1

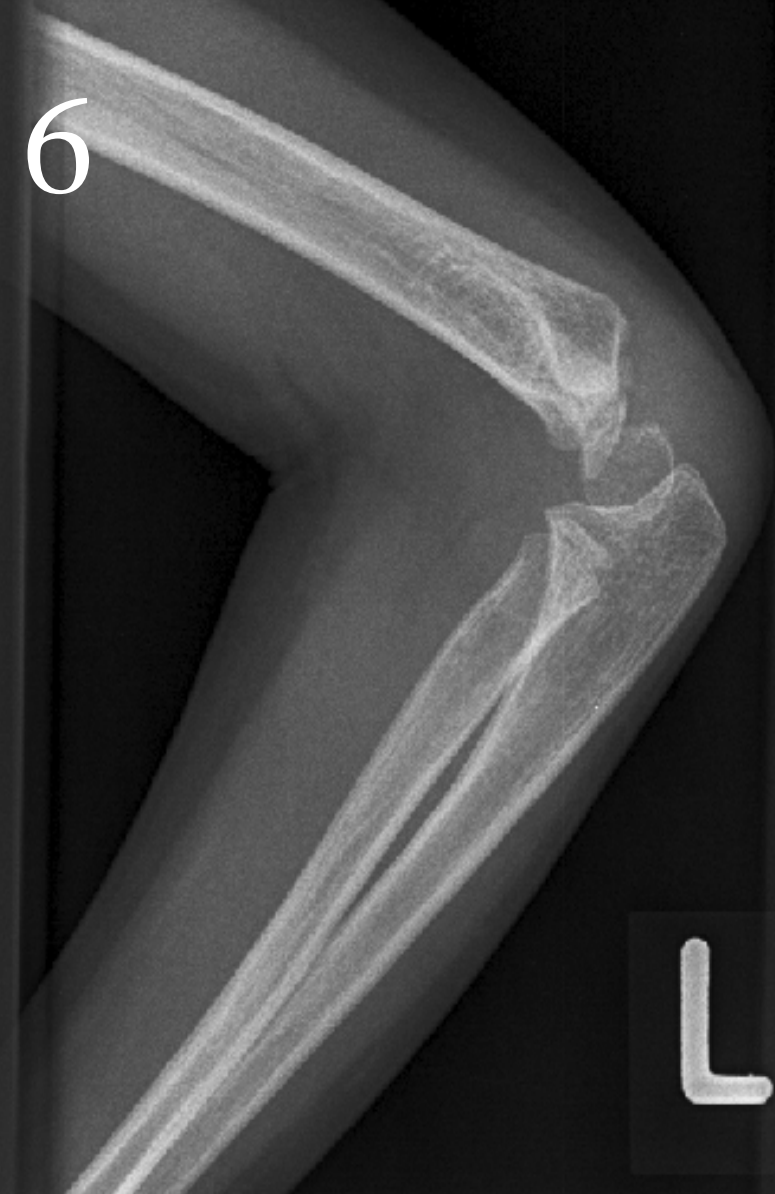

Q: 80% 
FN Brno -Detska nemocnice
ADC_5146

C: 2728
W:1856

ID:083849
Zarychtova Simona
Narozen:1999-12-23
Datum:2005-03-07
Cas:12:28:17
No.1

6

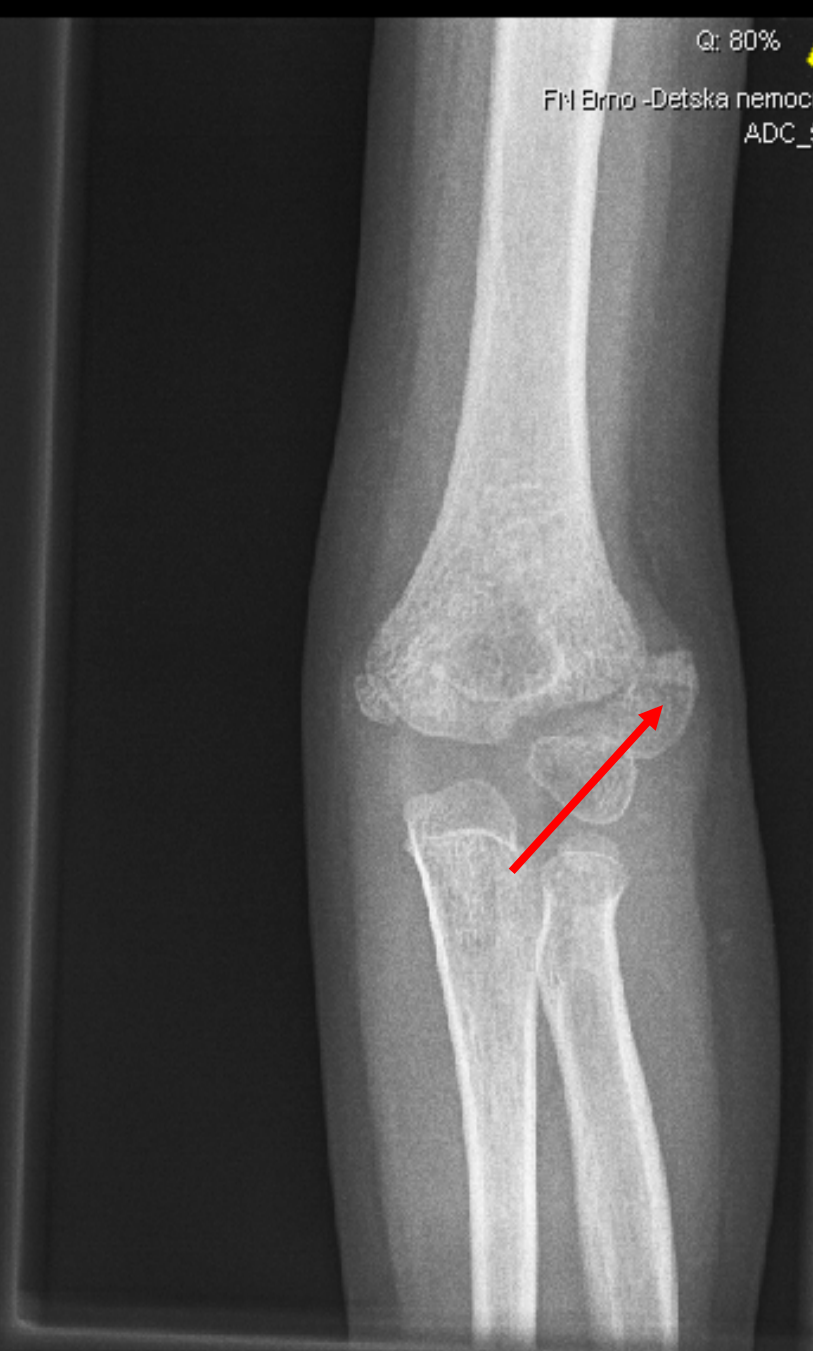

?

Q: 80%



FH Brno -Detska nemocnice
ADC_51xx



C: 2780
W: 1895

?


Zarychtova Simona
ID: 083849
DoB: 1999-12-23
2005-03-23
09:25:28
No. 66
2005-03-23

Q: 95%



Fak. detska nemocnice
SOMATOM PLUS 4

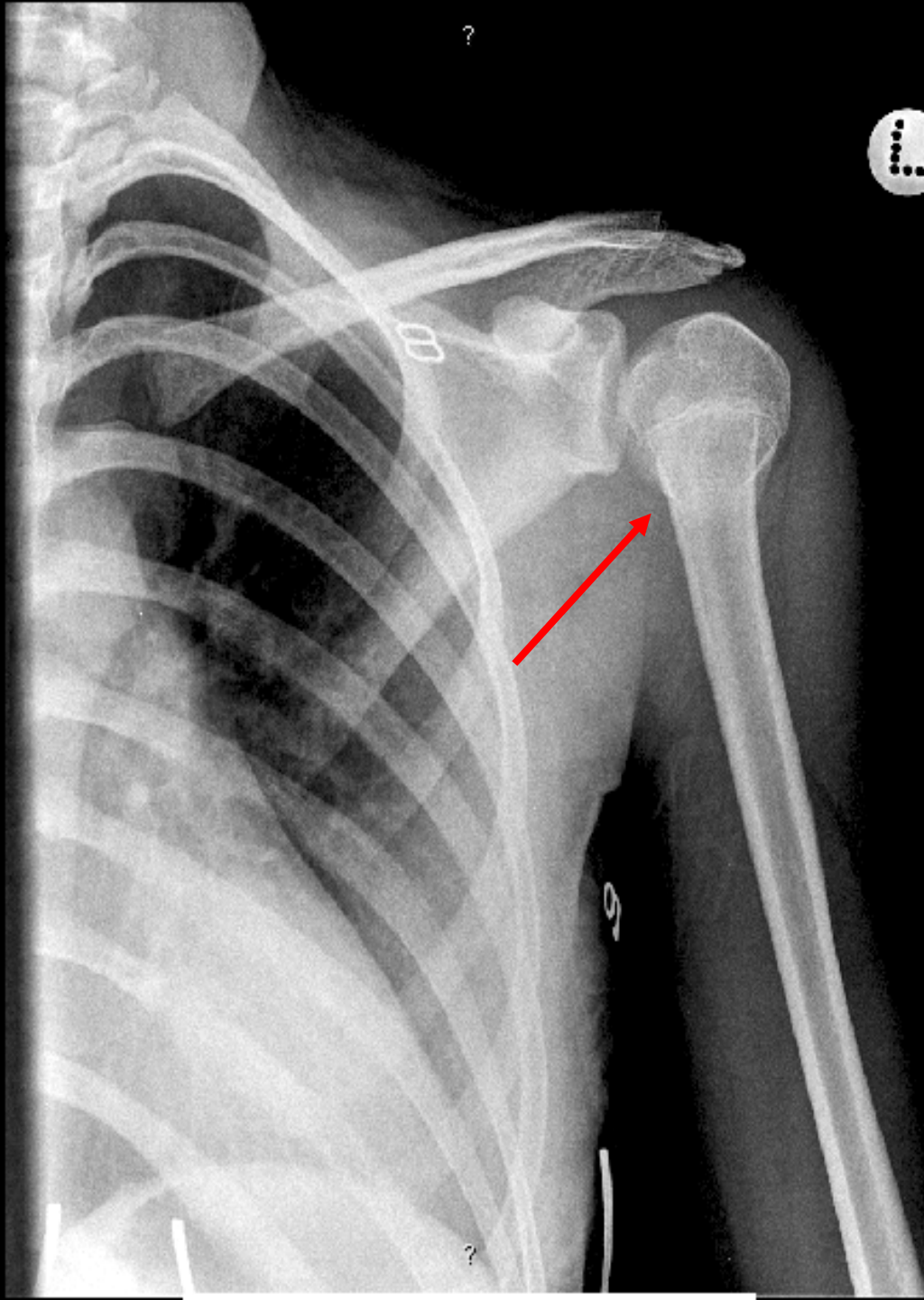
spin -18
tilt +2



C: 1100
W: 3000

ID:094973
Zemanova Veronika
Narozen:1990-09-24
Datum:2005-07-20
Cas:21:56:01
No.1

7



Q: 80%

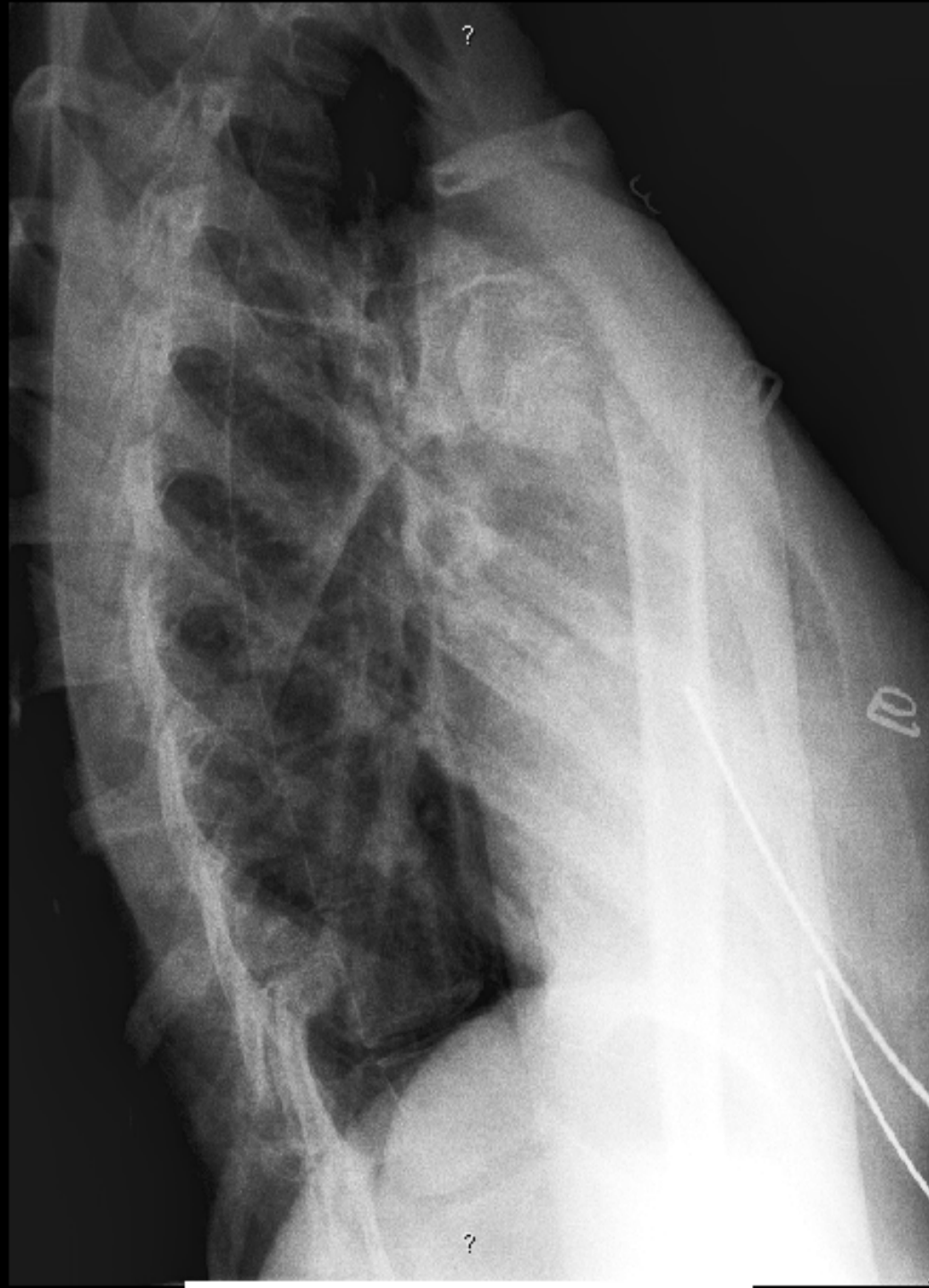


FN Brno -Detska nemocnice
ADC_5146



C: 2890
W: 1088

ID:094973
Zemanova Veronika
Narozen:1990-09-24
Datum:2005-07-20
Cas:22:09:59
No.1



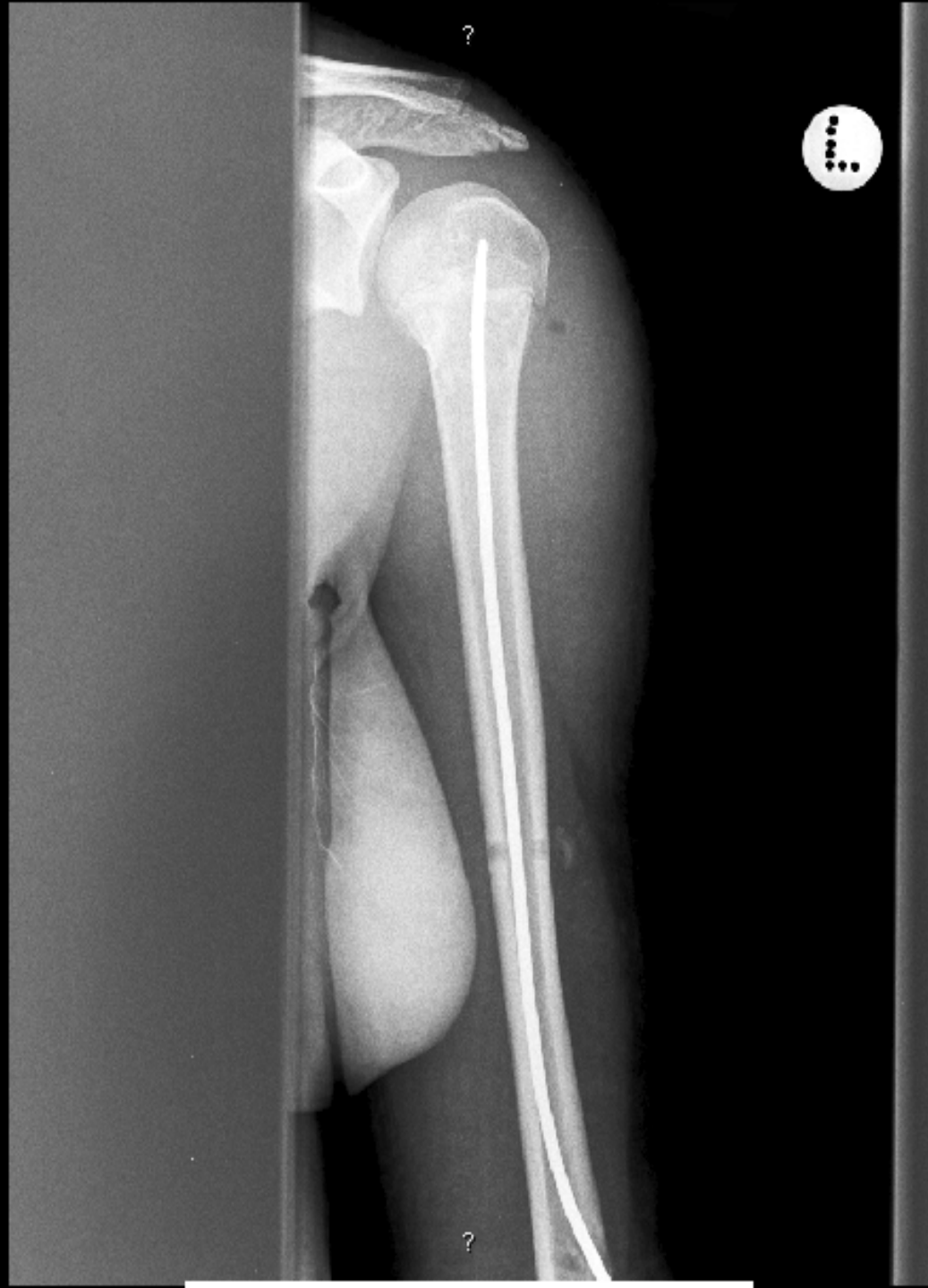Q: 80%



FN Brno -Detska nemocnice
ADC_5146

C: 3723
W: 807

ID:094973
Zemanova Veronika
Narozen:1990-09-24
Datum:2005-07-27
Cas:08:22:13
No.1



Q: 80%

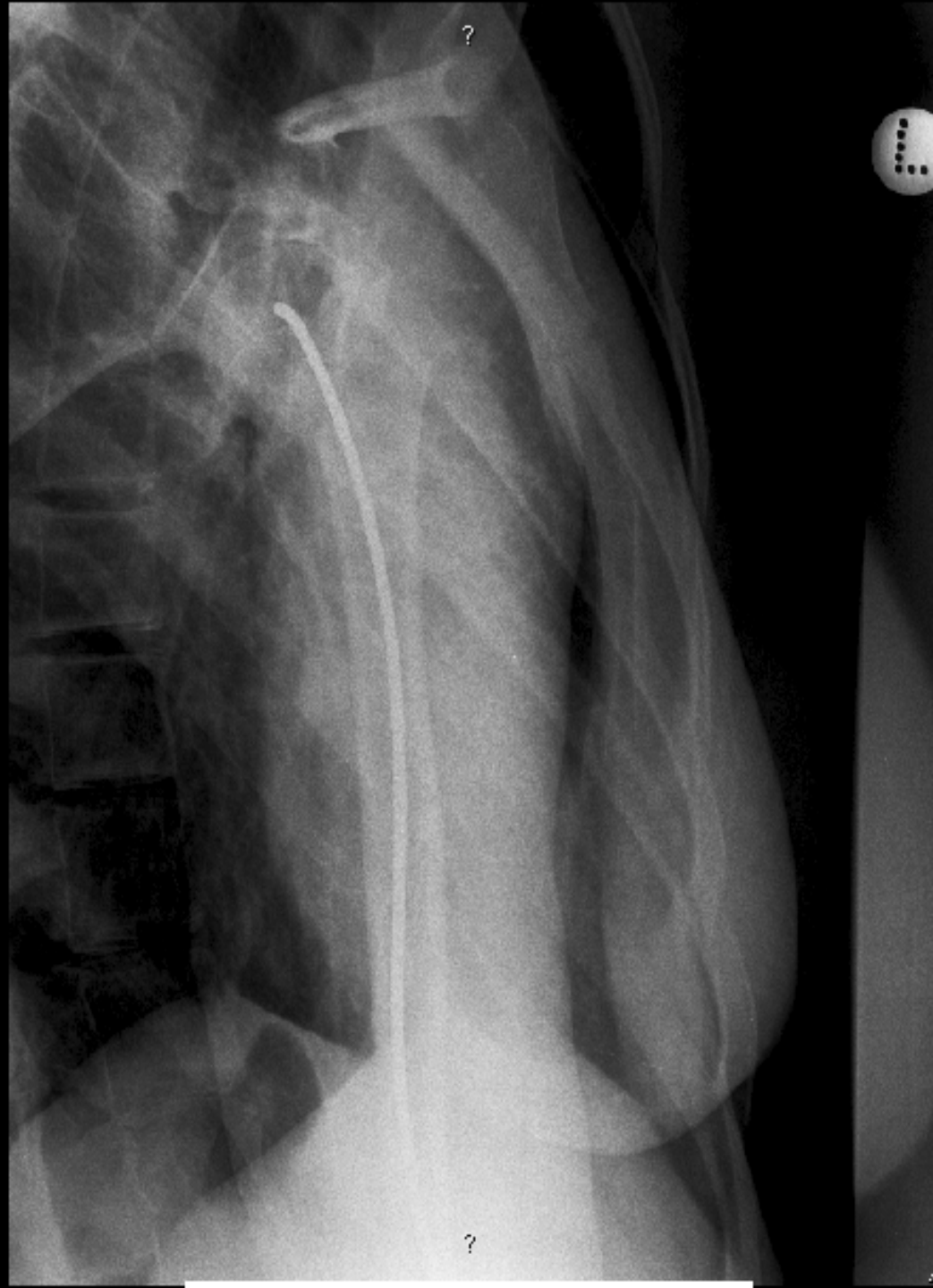

FN Brno -Detska nemocnice
ADC_5146



C: 3241
W: 1475

ID:094973
Zemanova Veronika
Narozen:1990-09-24
Datum:2005-07-27
Cas:08:23:15
No.1



Q: 80%



FN Brno -Detska nemocnice
ADC_5146

C: 3138
W: 1529

Thaisz Merlin
ID:082185
DoB:2004-04-01
2005-02-14
23:41:45
No.15

AH

Q: 90%

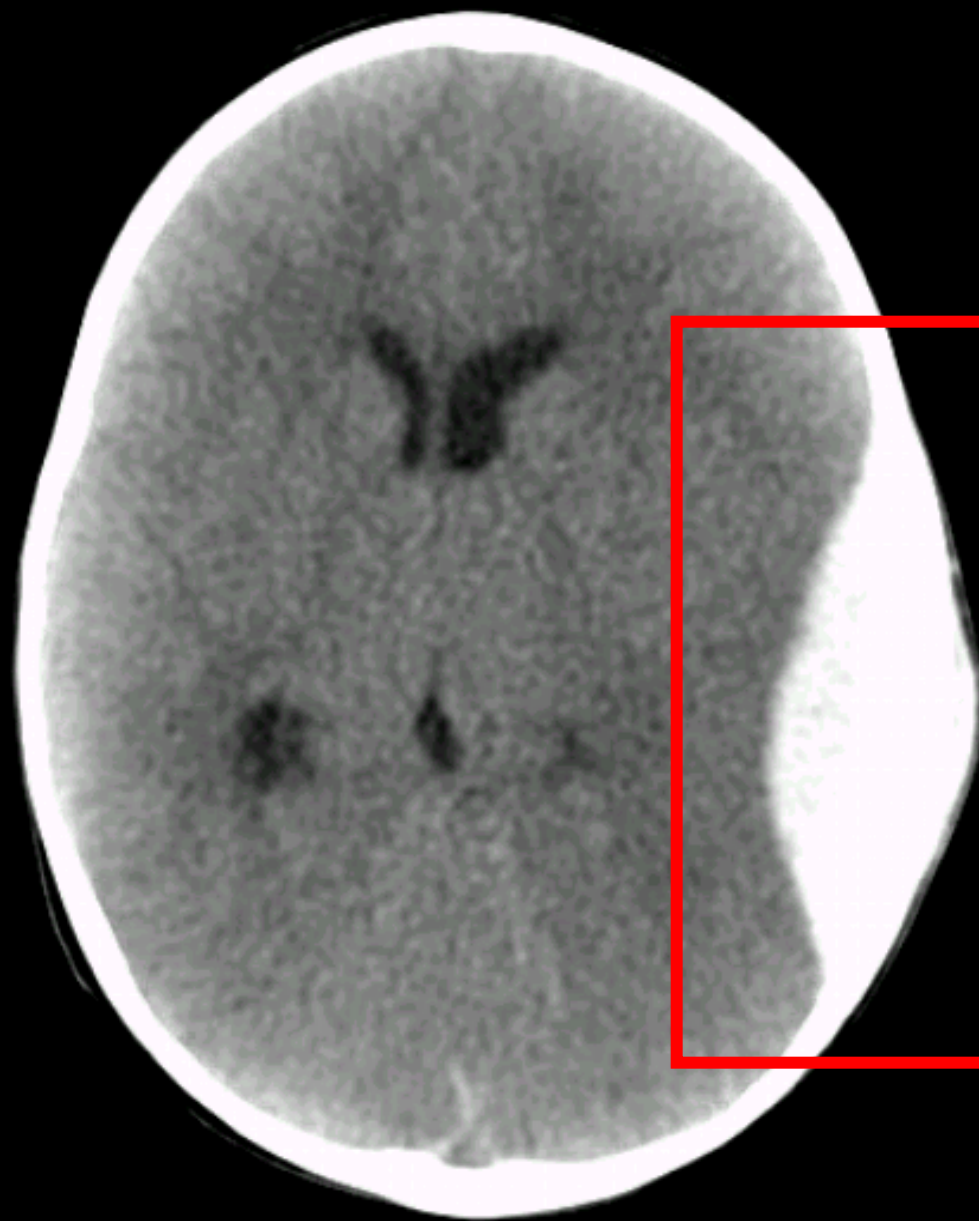

Fak. detska nemocnice
SOMATOM PLUS 4

8

R

L




RM
GT:-2
SP:350
SL:5
CM:

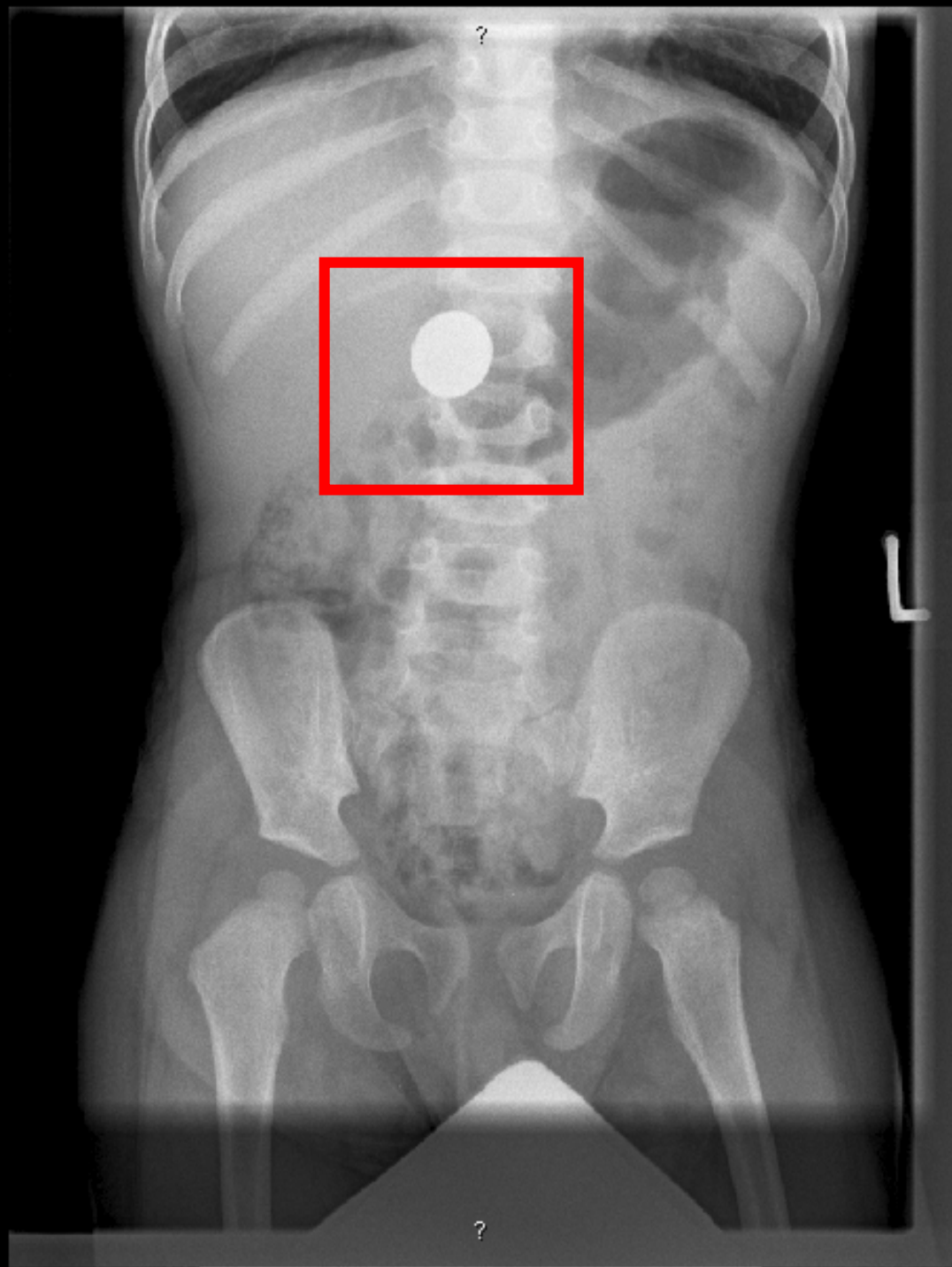
PF

C: 35
W: 80

ID:081582
Huser Tomas
Narozen:2003-06-03
Datum:2005-02-11
Cas:09:31:18
No.1

Q: 80% 
FN Brno -Detska nemocnice
ADC_5146

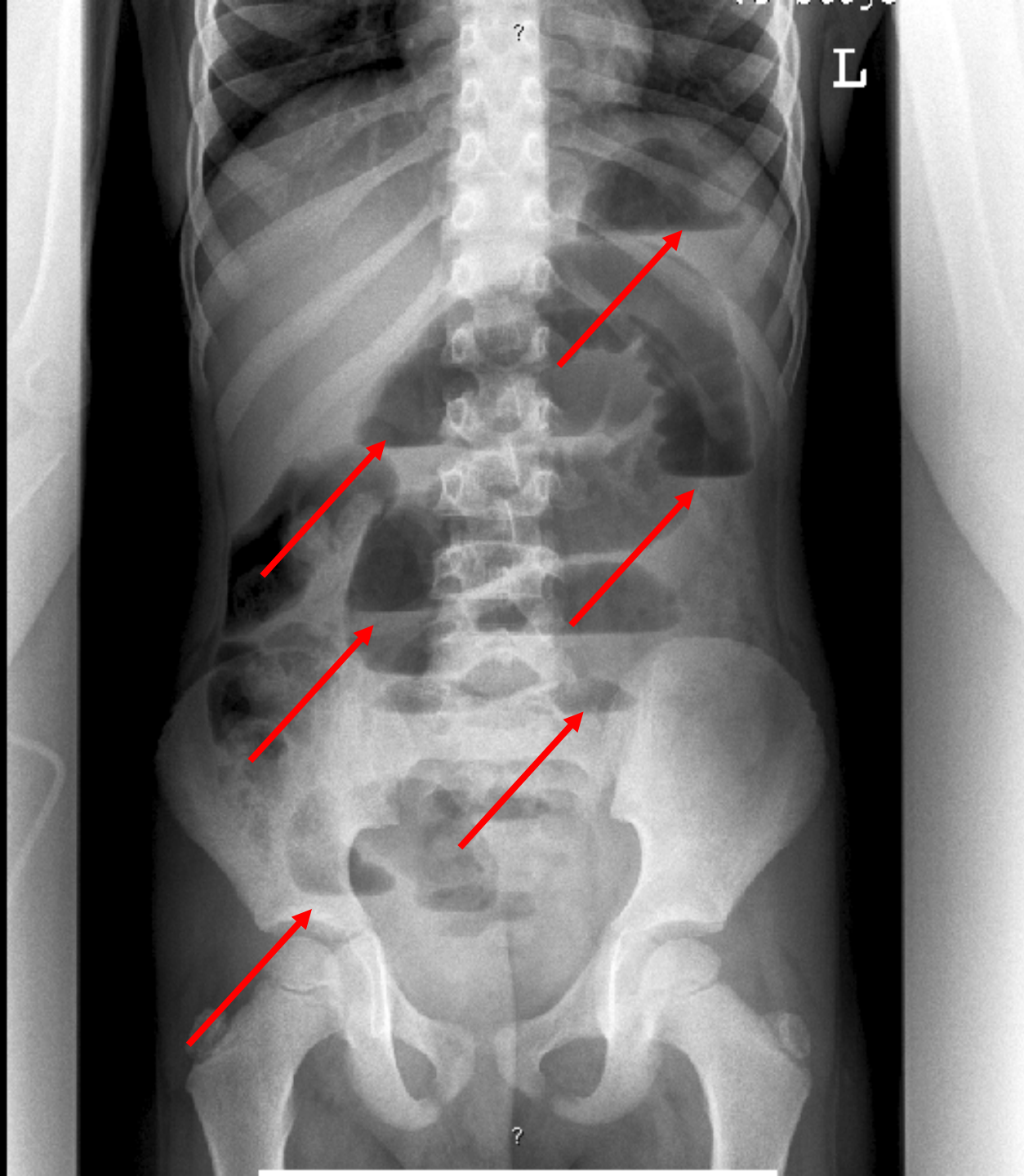
9




C: 2968
W: 1625

ID:002433
Vojta Jiri
Narozen:1999-11-30
Datum:2005-04-17
Cas:08:59:46
No.1

10



Q: 80% 
FN Brno -Detska nemocnice
ADC_5146

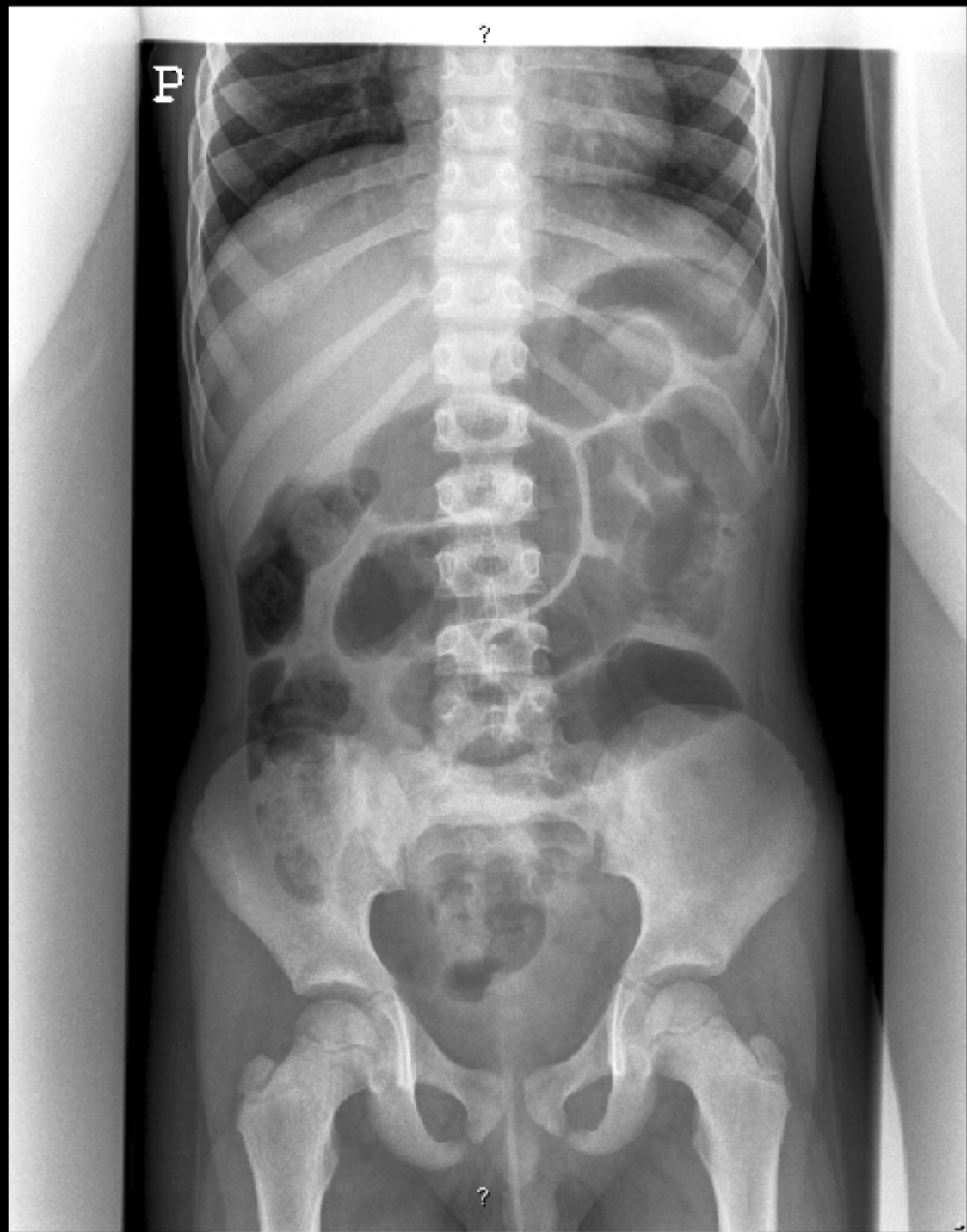C: 2426
W: 1865

ID:002433
Vojta Jiri
Narozen:1999-11-30
Datum:2005-04-17
Cas:08:55:08
No.1

Q: 80%



FN Brno -Detska nemocnice
ADC_5146



C: 2546
W: 2075

Thank you for your attention